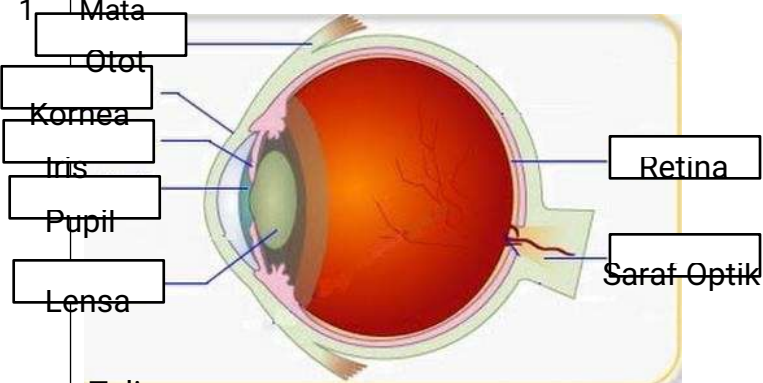
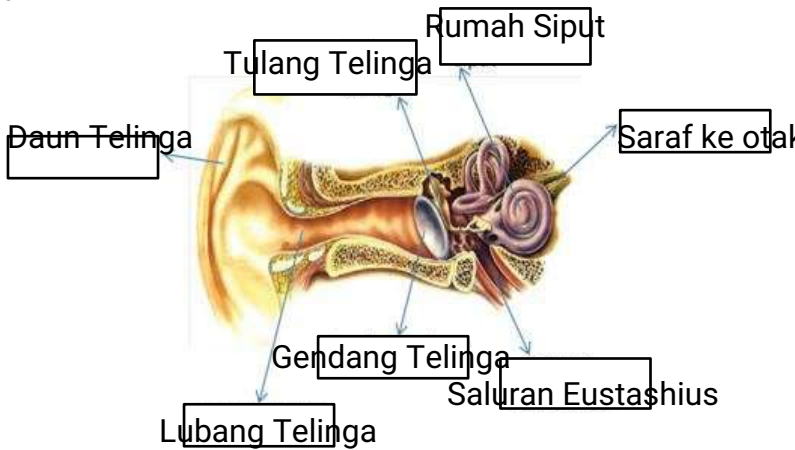
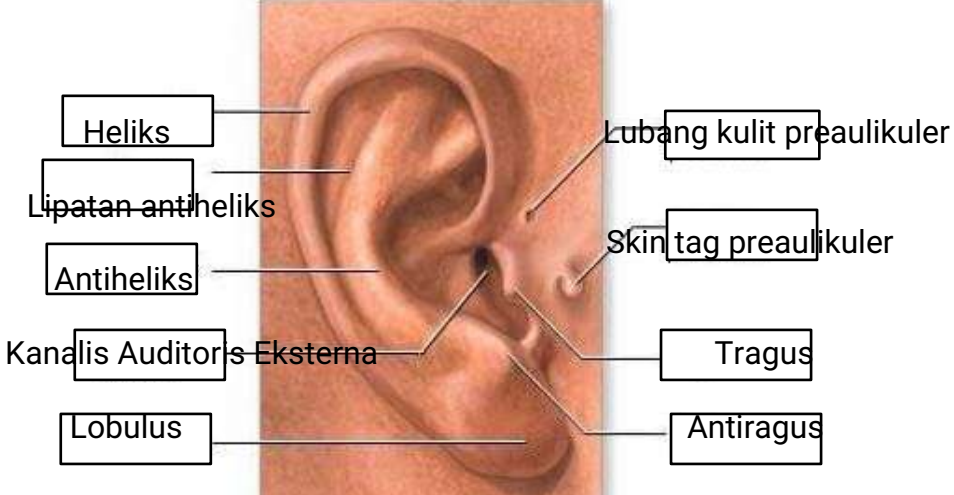
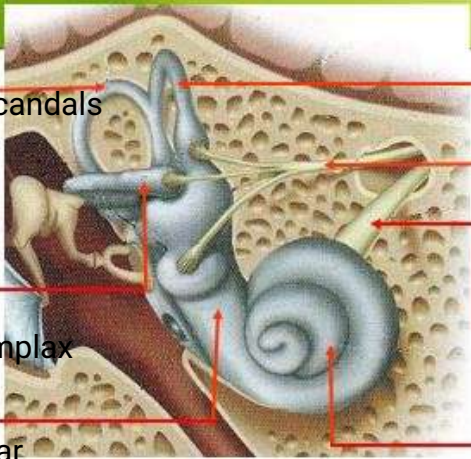
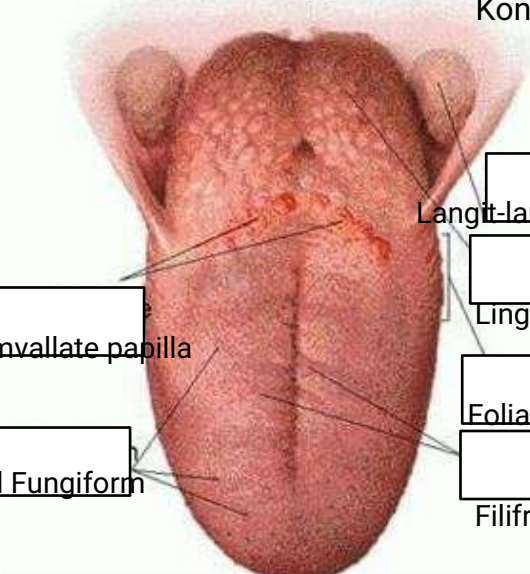


WORKSHEETS (LEMBAR KERJA)

Mata Kuliah	: Anatomi
Materi	: Anatomi Panca Indra
NIM>Nama Mahasiswa	: PUTRI WAHYUNING PANGESTI 2110101027

No	Keterangan	Pembahasan
1	<p>Mata</p> <p>Otot</p> <p>Kornea</p> <p>Iris</p> <p>Pupil</p> <p>Lensa</p>	
	<p>Telinga</p>	
		

No	Keterangan	Pembahasan
<p>within</p> <p>Vestibulus complex</p> <p>Tingkap Bundar</p>	 <p>Semioisoulas candals</p> <p>[]</p> <p>[]</p>	<p>Semicircules cluet</p> <p>anterior semicor</p> <p>malicus, incus, stapes</p> <p>[]</p> <p>Saraf Kolea</p> <p>[]</p>
	<p>Circumvallate papilla</p> <p>Papil Fungiform</p>	<p>Konklec (Rumah Siput)</p>  <p>Langit-langit Tenggorokan</p> <p>[]</p> <p>Lingual Tongsil</p> <p>Foliate Papillae</p> <p>[]</p> <p>Filifrom papillae</p>