

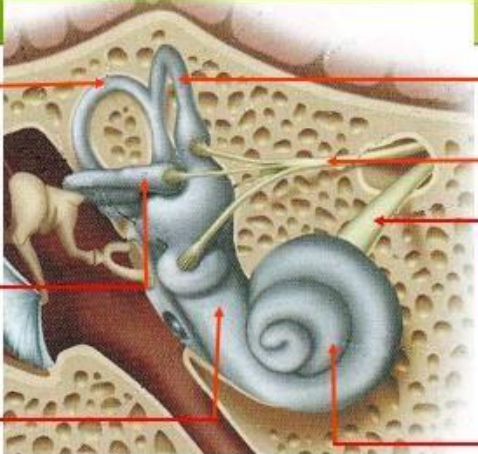
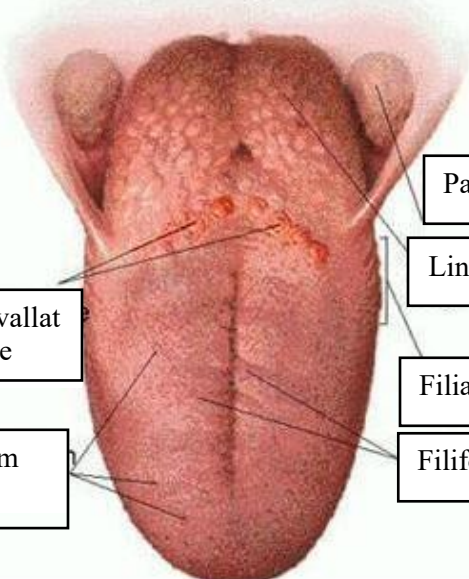
WORKSHEETS (LEMBAR KERJA)

Mata Kuliah	: Anatomi
Materi	: Anatomi Panca Indra
NIM>Nama Mahasiswa	: 2110101028/ LEDY SUPRIHATIN

No	Keterangan	Pembahasan
----	------------	------------

1	Mata	
	otot	
	cornea	
	iris	
	pupil	
	lensa	

Telinga

No	Keterangan	Pembahasan
	<p data-bbox="304 320 456 405">Semicircular canals</p> <p data-bbox="304 488 456 573">Vestibular complex</p> <p data-bbox="304 656 456 730">Tingkap bundar</p>	 <p data-bbox="999 331 1350 398">Semicircular duct within anterior semicircular</p> <p data-bbox="999 450 1270 555">Vestibular branch (malleus, incus, dan stapes)</p> <p data-bbox="999 566 1270 633">Cochlear branch</p> <p data-bbox="999 663 1158 723">cochlea</p>
		 <p data-bbox="480 1032 671 1115">Circumvallate papillae</p> <p data-bbox="464 1182 655 1265">Fungiform papillae</p> <p data-bbox="1015 898 1206 958">Palatine tonsil</p> <p data-bbox="1015 981 1238 1041">Lingual tonsil</p> <p data-bbox="999 1099 1190 1160">Filiform papillae</p> <p data-bbox="999 1182 1222 1243">Filiform papillae</p>