

Mata Kuliah	WORKSHEETS (LEMBAR KERJA)
	: Anatomi
Materi	: Anatomi Panca Indra
NIM>Nama Mahasiswa	: 2110101019 / Oea Resita

No	Keterangan	Pembahasan
----	------------	------------

1 Mata

Labels on the left: **otot mata**, **Kornea**, **Iris**, **Pupil**, **Lensa**

Labels on the right: **Retina**, **Saraf**

Telinga

Labels on the left: **Aurikula**, **Daun telinga**

Labels on the right: **Rumah siput**, **Ossicula Auditoris: Incus, Malleus, Stapes**, **Saraf ke otak**

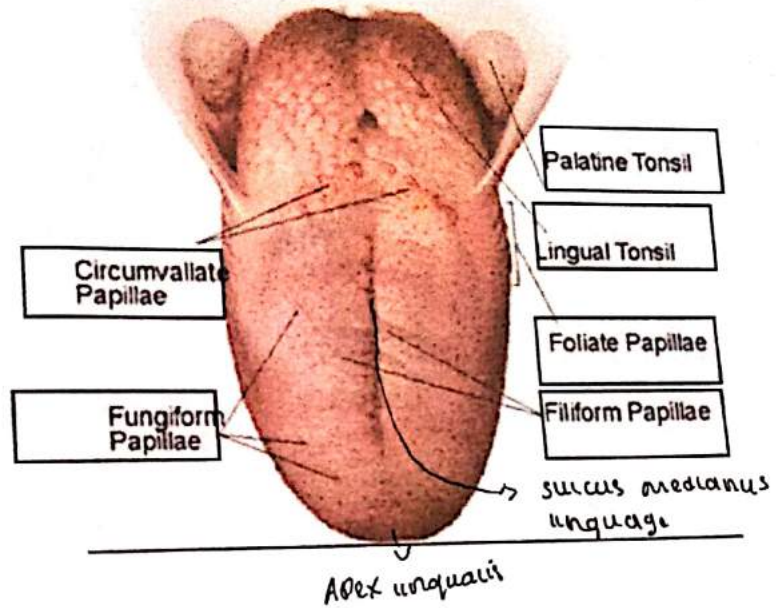
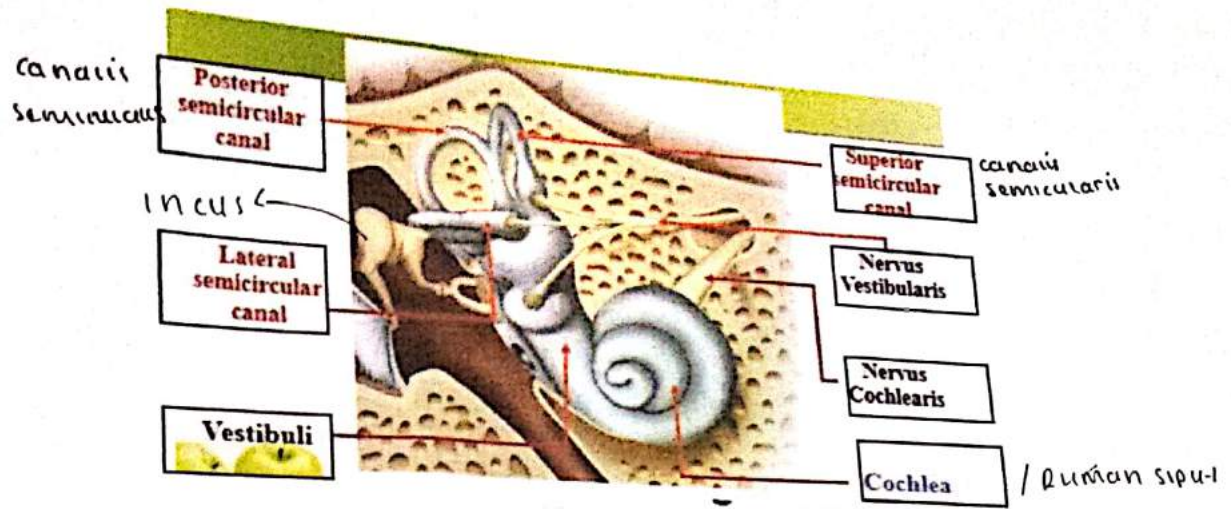
Labels at the bottom: **Mearus Akustikus Eksternus**, **Lubang telinga**, **Gendang telinga**, **Membran timpani**, **Saluran eustachius**

Labels on the left: **Heliks**, **Lipatan antiheliks scapula**, **Antiheliks**, **analis auditorius eksterna**, **Lobulus auricularis**

Labels on the right: **Lubang kulit preaurikuler**, **Skin tag preaurikuler**, **Tragus**, **Antitragus**

Handwritten notes: **SKIN TAG Preaurikuler**, **↳ insesua intragica**

No	Keterangan	Pembahasan
----	------------	------------



Telinga

1. Telinga Bagian luar (Auris eksterna)

- A. Aurikula (Daun telinga)
- B. Meatus Akustikus Eksterna
- C. Membran Tympany

2. Telinga Bagian Tengah (Auris Media)

- A. Cavum Tympani
- B. Antrum Tympani
- C. Tuba Eustachius

Fungsi : pendengaran
(keselimbangan -vii)