

WORKSHEETS (LEMBAR KERJA)

Mata Kuliah	: Anatomi
Materi	: Anatomi Panca Indra
NIM>Nama Mahasiswa	: 2110101045 / Nadia Putri Anggraheni

No	Keterangan	Pembahasan
----	------------	------------

1 Mata

Labels in diagram:

- Superior rectus muscle
- Cornea
- Iris
- Pupil
- Lens
- Retina
- Optic nerve

Telinga

Labels in diagram:

- Auricle (daun telinga)
- Cochlea
- Auditory ossicles
- Vestibulocochlear nerve
- Tympanic membrane
- Ear canal (gendang telinga)
- Pharyngotympanic (auditory) tube

Labels in diagram:

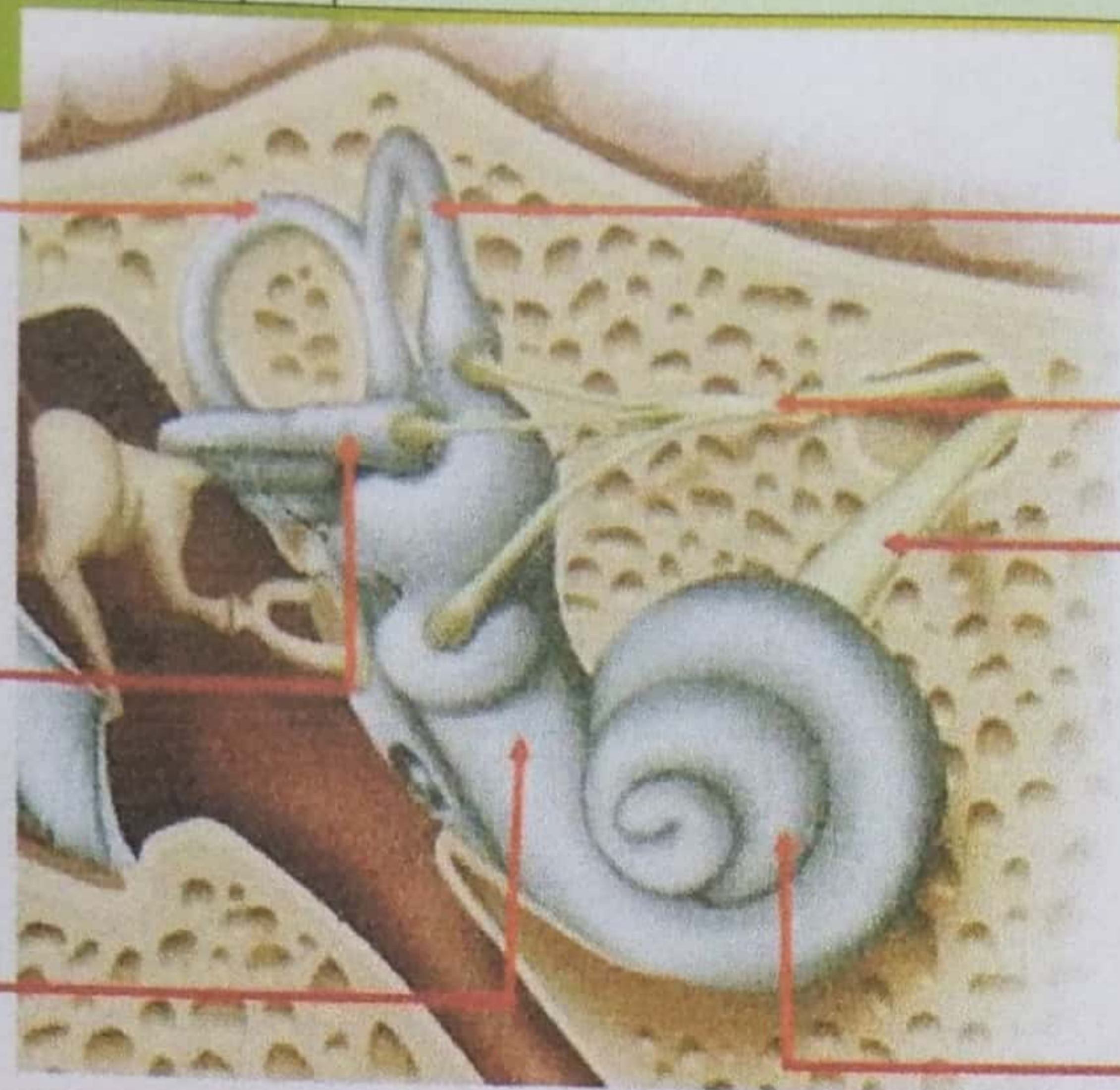- Helix
- Scapha
- Anti helix
- Auditory meatus (ear hole)
- Lobule
- lubang kulit preaurikuler
- Skin tag preaurikuler
- Tragus
- Anti tragus

No	Keterangan	Pembahasan
----	------------	------------

Posterior  
semicircular  
canal

Lateral  
semicircular  
canal

Vestibular  
complex

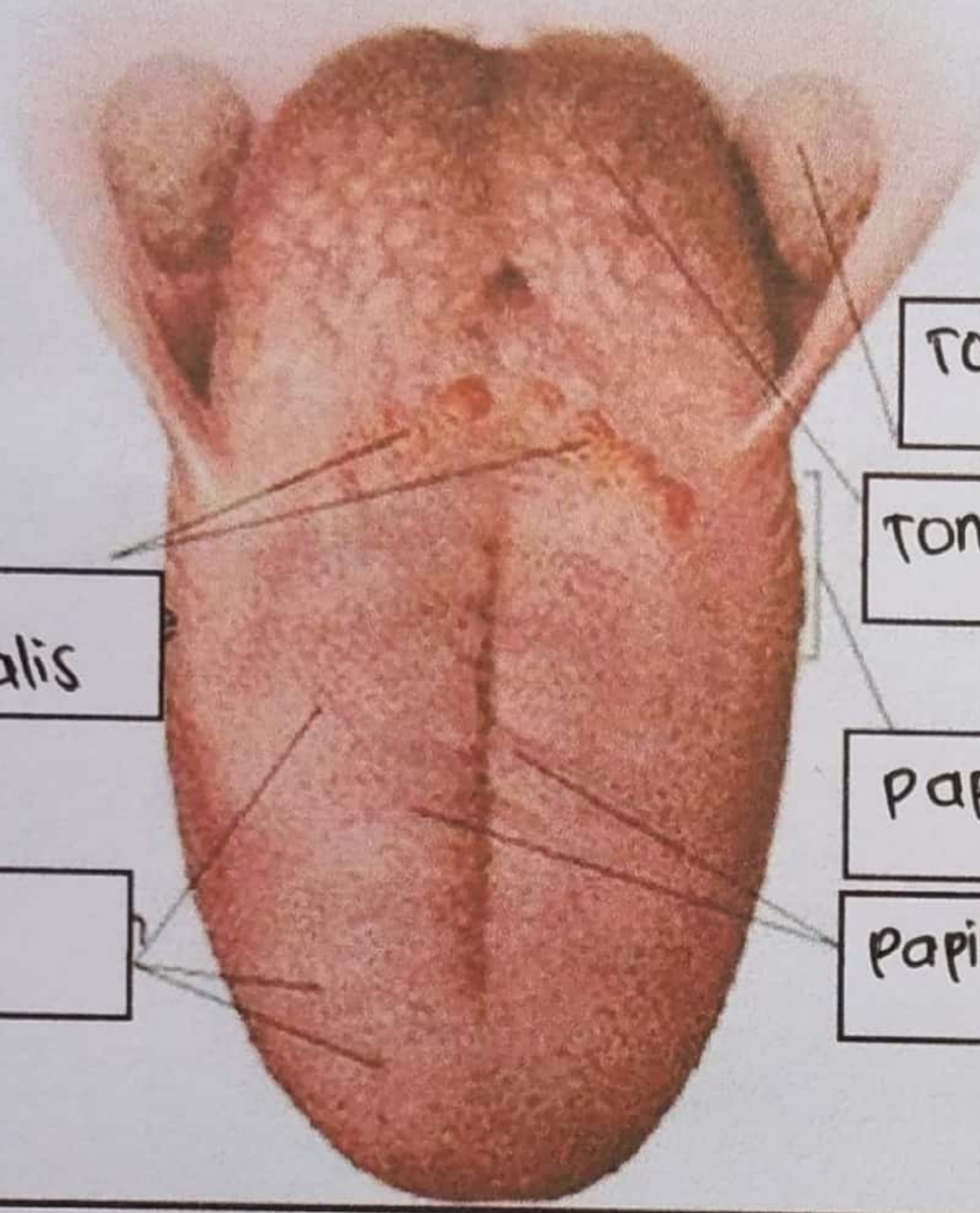


Superior  
semicircular  
canal

Vestibular  
nerve

Cochlear  
nerve

Cochlea



Sukus  
terminalis

Dorsum  
linguae

Tonsila palatina

Tonsila lingualis

Papilo circumvalate

Papilia fungiformis.