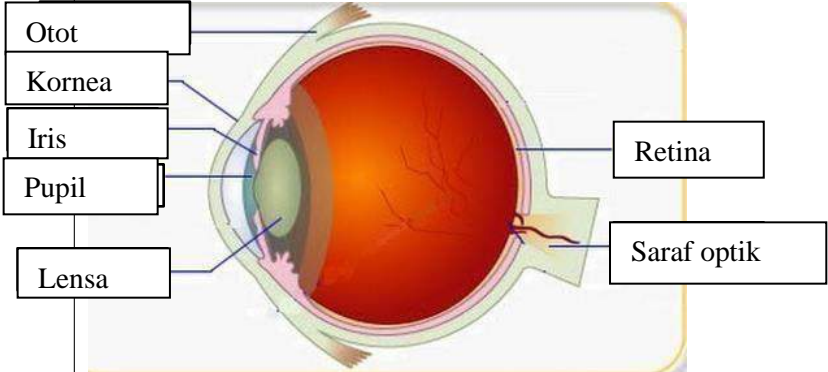
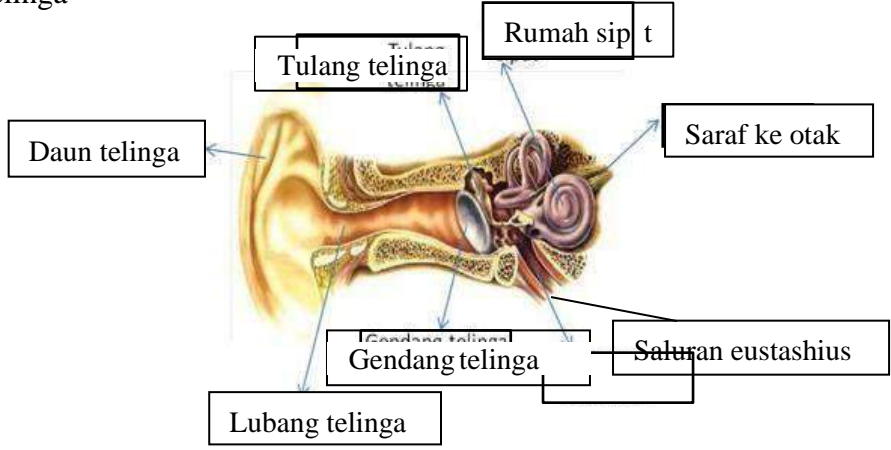
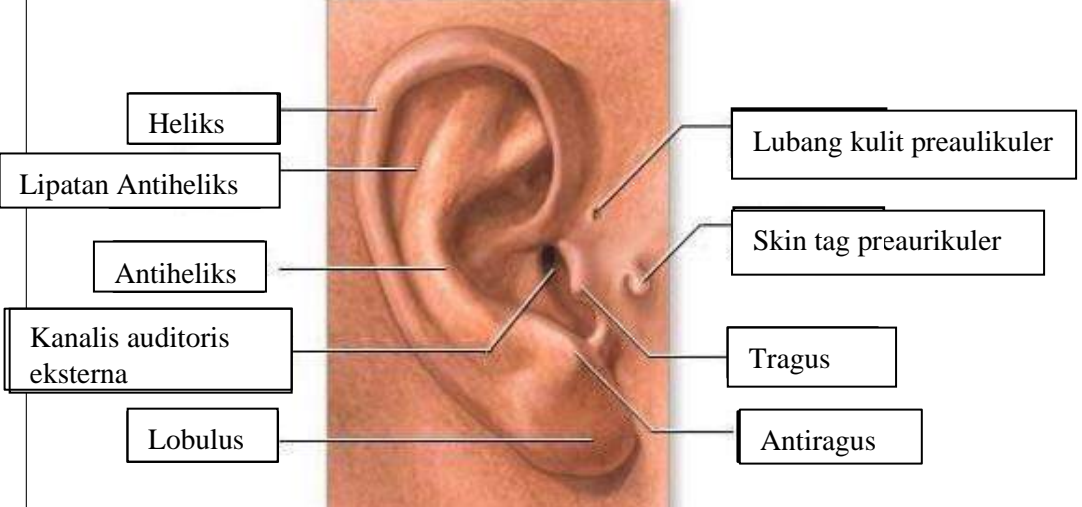



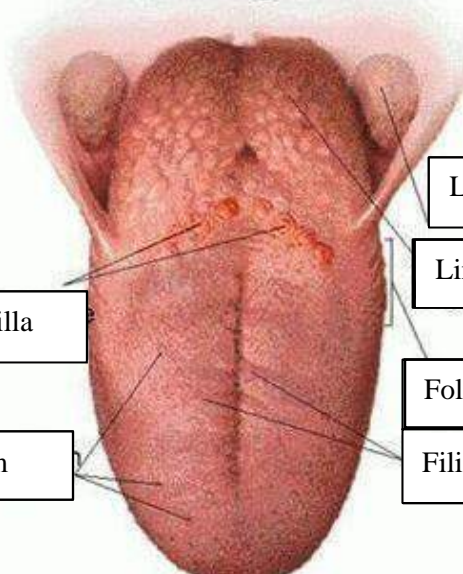
**WORKSHEETS (LEMBAR KERJA)**

<b>Mata Kuliah</b>	: Anatomi
<b>Materi</b>	: Anatomi Panca Indra
<b>NIM&gt;Nama Mahasiswa</b>	: 2110101002 Jasmin Linadi Yulia Putri

No	Keterangan	Pembahasan
1	Mata	 <p>Diagram of the human eye showing internal structures. Labels include: Otot (Muscle), Kornea (Cornea), Iris, Pupil, Lensa (Lens), Retina, and Saraf optik (Optic nerve).</p>
	Telinga	 <p>Diagram of the human ear showing internal structures. Labels include: Daun telinga (Pinna), Tulang telinga (Ear bones), Rumah sipit (Middle ear), Saraf ke otak (Nerve to brain), Saluran eustashius (Eustachian tube), Gendang telinga (Eardrum), and Lubang telinga (Ear canal).</p>
		 <p>Diagram of the external ear showing external structures. Labels include: Heliks (Helix), Lipatan Antiheliks (Antihelical fold), Antiheliks (Antihelix), Kanalis auditoris eksterna (External auditory canal), Lobulus (Lobule), Lubang kulit preaulikuler (Preauricular skin pit), Skin tag preaurikuler (Preauricular skin tag), Tragus, and Antiragus.</p>

No	Keterangan	Pembahasan
----	------------	------------

		<p data-bbox="271 313 462 425">Semicircular Canals</p> <p data-bbox="247 481 454 571">Vestibular complex</p> <p data-bbox="223 638 454 716">Tingkap bundar</p> <p data-bbox="1005 324 1332 414">Semicircular duct within anterior semicor</p> <p data-bbox="989 436 1300 571">1. Malleus 2. Incus 3. Stapes</p> <p data-bbox="997 582 1212 638">Saraf kolesera</p> <p data-bbox="1005 660 1324 728">Konklev (rumah siput)</p>
--	---	---

		<p data-bbox="1021 896 1356 952">Langit-langit tenggorokan</p> <p data-bbox="1005 974 1244 1041">Lingual tonsil</p> <p data-bbox="343 1030 678 1097">Circumvallate papilla</p> <p data-bbox="383 1164 662 1232">Papil fungiform</p> <p data-bbox="989 1097 1244 1164">Foliate papillae</p> <p data-bbox="989 1176 1244 1243">Filiform papillae</p>
--	---	--