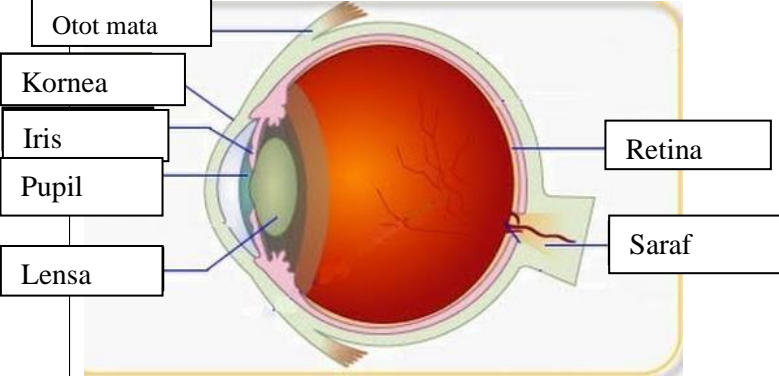
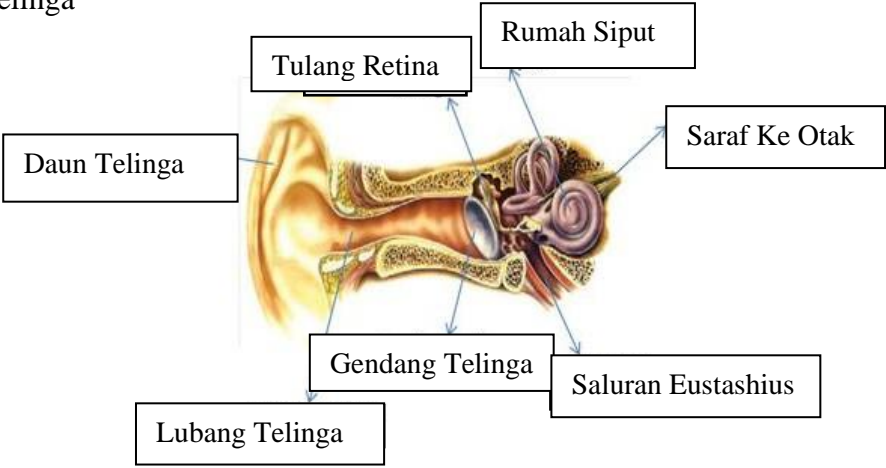
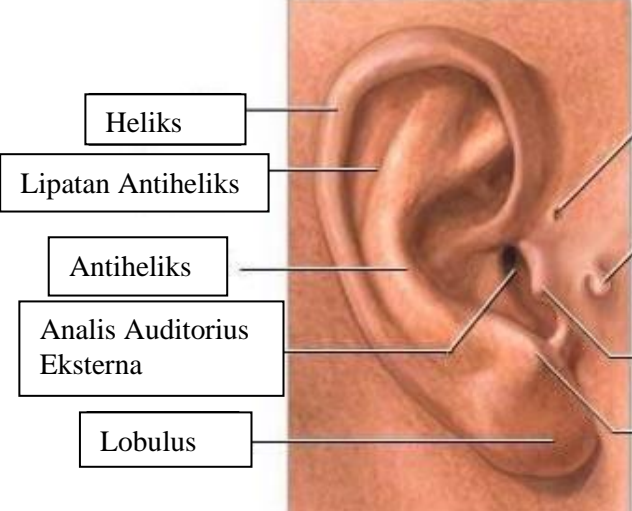
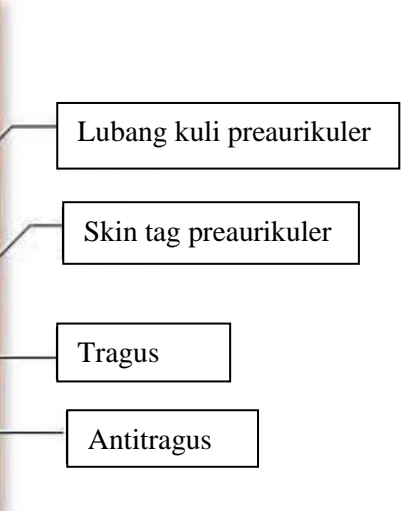
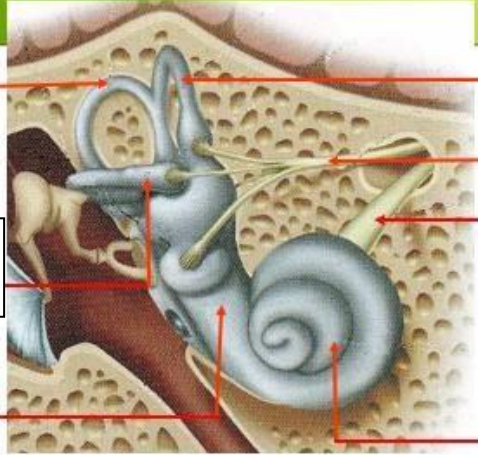


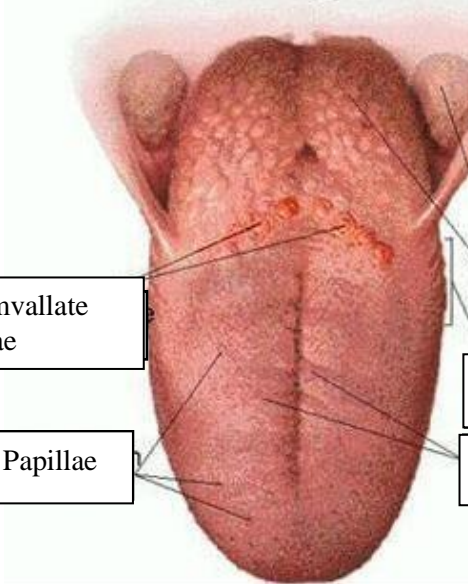
WORKSHEETS (LEMBAR KERJA)

Mata Kuliah	: Anatomi
Materi	: Anatomi Panca Indra
NIM>Nama Mahasiswa	: ALIFFAH MUSFIROTUN AZZAHROH/2110101020

No	Keterangan	Pembahasan
1	<p>Mata</p> 	
	<p>Telinga</p> 	
		

No	Keterangan	Pembahasan
----	------------	------------

<p>Posterior Semicircular Canal</p>		<p>Superior Semicircular Canal</p>
<p>Lateral Semicircular Canal</p>		<p>Nervus Vestibularis</p>
<p>Vestibuli</p>		<p>Nervus Cochlearis</p>
		<p>Cochlea</p>

<p>Circumvallate Papillae</p>		<p>Palatine Tonsil</p>
<p>Fungiform Papillae</p>		<p>Lingual Tonsil</p>
		<p>Foliate Papillae</p>
		<p>Filliform Papillae</p>