

**WORKSHEETS (LEMBAR KERJA)**

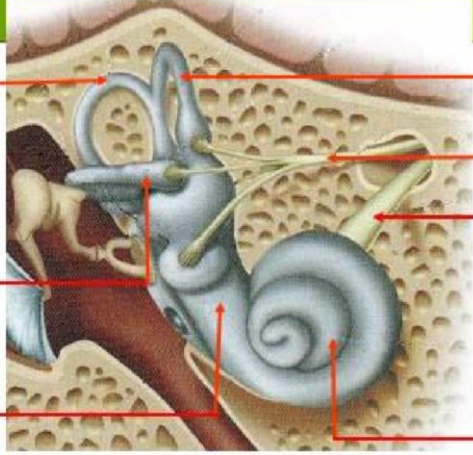
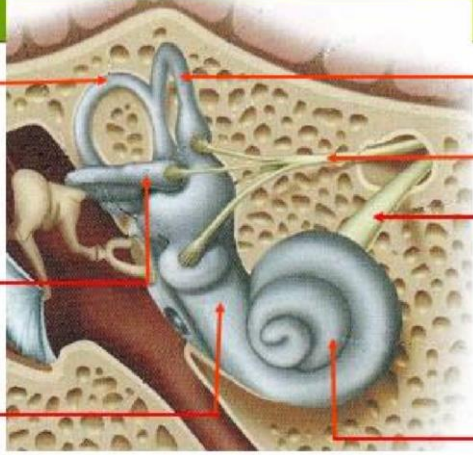
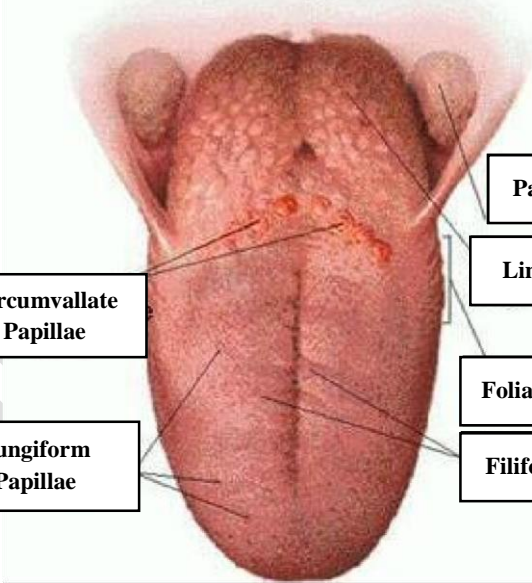
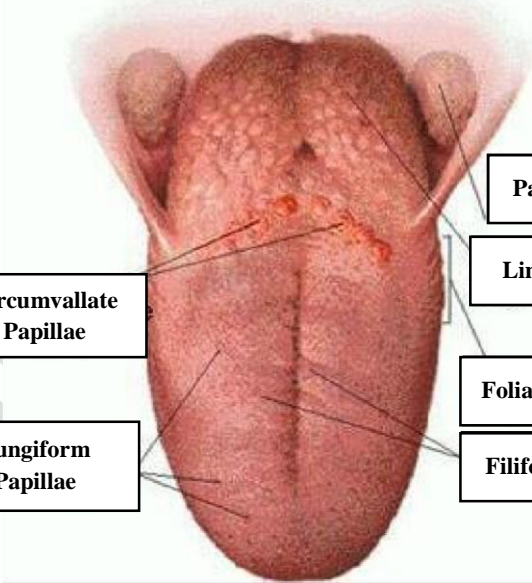
<b>Mata Kuliah</b>	<b>: Anatomi</b>
<b>Materi</b>	<b>: Anatomi Panca Indra</b>
<b>NIM&gt;Nama Mahasiswa</b>	<b>: 2110101023 / Amalia Zidny</b>

No	Keterangan	Pembahasan
----	------------	------------

1	Mata	<p>Anatomical diagram of the human eye showing internal structures. Labels on the left: Otot mata, Kornea, Iris, Pupil, Lensa. Labels on the right: Retina, Syaraf.</p>
---	------	---

	Telinga	<p>Anatomical diagram of the middle ear showing the ossicles and other structures. Labels: Daun telinga, Tulang telinga, Rumah siput, Saraf ke otak, Gendang telinga, Saluran eustashius, Lubang telinga.</p>
--	---------	---

		<p>Anatomical diagram of the external ear showing its various parts. Labels on the left: Heliks, Lipatan antiheliks, Antiheliks, Analis auditorius eksterna, Lobulus. Labels on the right: Lubang kulil preaulikuler, Skin tag preaurikuler, Tragus, Antitragus.</p>
--	--	--

No	Keterangan	Pembahasan
	 <p data-bbox="231 320 464 409">Posterior semicircular canal</p> <p data-bbox="225 495 464 584">Lateral semicircular canal</p> <p data-bbox="276 669 458 734">Vestibuli</p>	 <p data-bbox="991 331 1259 409">Superior semicircular canal</p> <p data-bbox="991 450 1233 510">Nervus vestibularis</p> <p data-bbox="991 573 1222 633">Nervus cochlearis</p> <p data-bbox="991 669 1161 734">Cochlea</p>
	 <p data-bbox="467 1021 671 1099">Circumvallate Papillae</p> <p data-bbox="456 1167 667 1245">Fungiform Papillae</p>	 <p data-bbox="1015 898 1219 958">Palatine Tonsil</p> <p data-bbox="999 987 1214 1048">Lingual Tonsil</p> <p data-bbox="991 1111 1190 1171">Foliate Papillae</p> <p data-bbox="991 1189 1214 1249">Filiform Papillae</p>