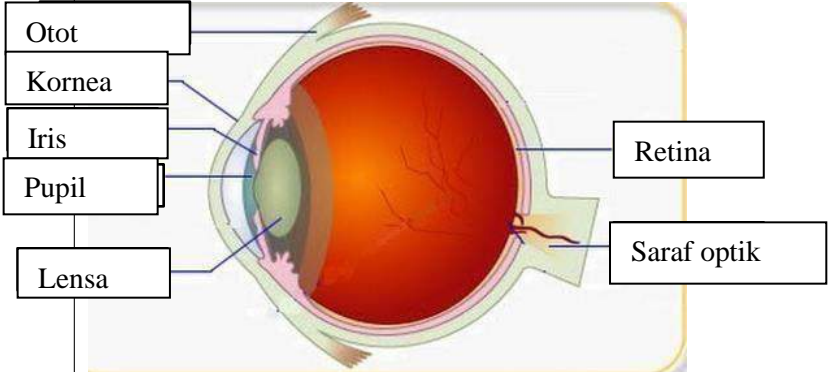
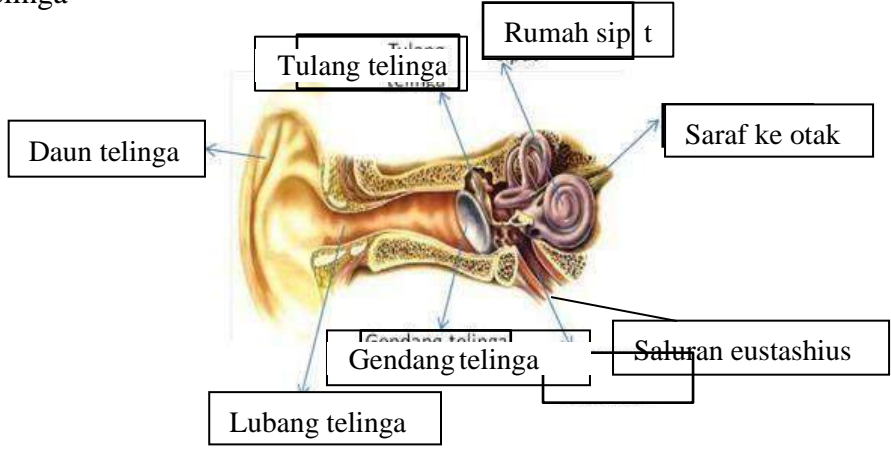
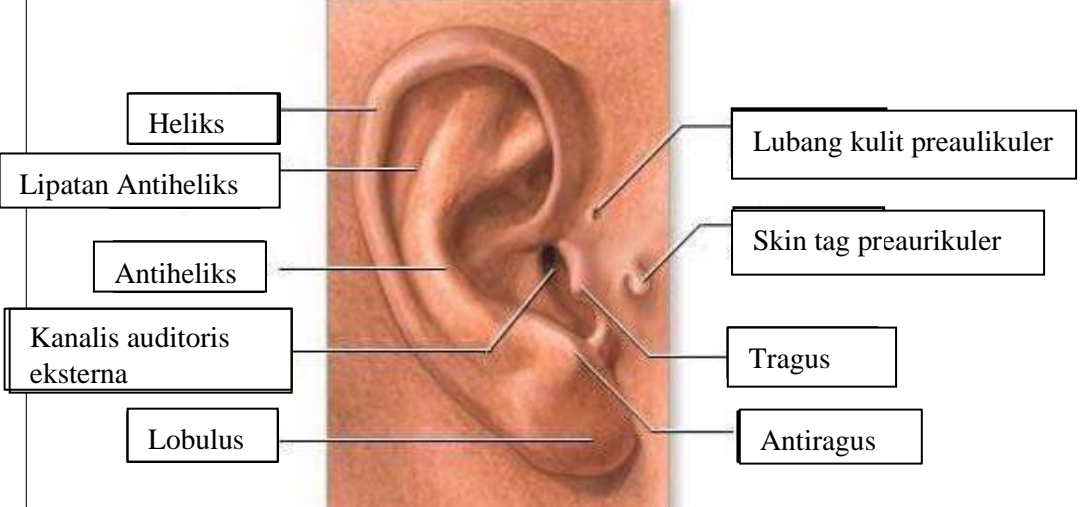

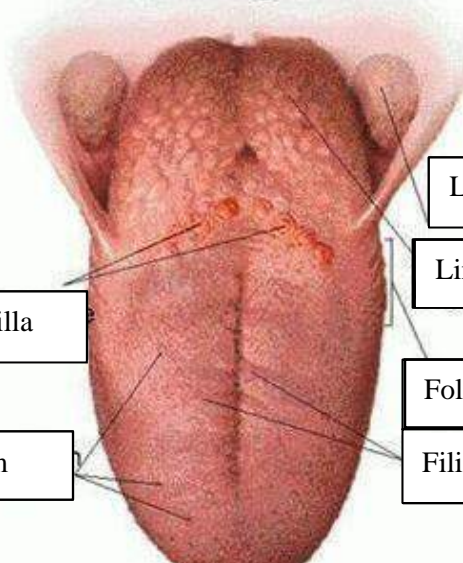


WORKSHEETS (LEMBAR KERJA)

Mata Kuliah	: Anatomi
Materi	: Anatomi Panca Indra
NIM>Nama Mahasiswa	: 2110101001 SHAFIRDA INAYATI

No	Keterangan	Pembahasan
1	Mata	 <p>Diagram of the human eye showing internal structures. Labels include: Otot (Muscle), Kornea (Cornea), Iris, Pupil, Lensa (Lens), Retina, and Saraf optik (Optic nerve).</p>
	Telinga	 <p>Diagram of the human ear showing internal structures. Labels include: Daun telinga (Pinna), Tulang telinga (Ear bones), Rumah sipit (Middle ear), Saraf ke otak (Nerve to brain), Saluran eustachius (Eustachian tube), Gendang telinga (Eardrum), and Lubang telinga (Ear canal).</p>
		 <p>Diagram of the external ear showing external structures. Labels include: Heliks (Helix), Lipatan Antiheliks (Antihelical fold), Antiheliks (Antihelix), Kanalis auditoris eksterna (External auditory canal), Lobulus (Lobule), Lubang kulit preaulikuler (Preauricular skin pit), Skin tag preaurikuler (Preauricular skin tag), Tragus, and Antiragus.</p>

No	Keterangan	Pembahasan
	<p>Semioisoulas Candals</p> <p>Vestsbulcus complax</p> <p>Tingkap bundar</p>	 <p>Semicircules cluct within anterios semicor</p> <p>1. Malicus 2. Incus 3. Stapes</p> <p>Saraf kolea</p> <p>Konklec (rumah siput)</p>
	<p>Circumvallate papilla</p> <p>Papil fungiform</p>	 <p>Langit-langit tenggorokan</p> <p>Lingual tonsil</p> <p>Foliate papillae</p> <p>Filiform papillae</p>