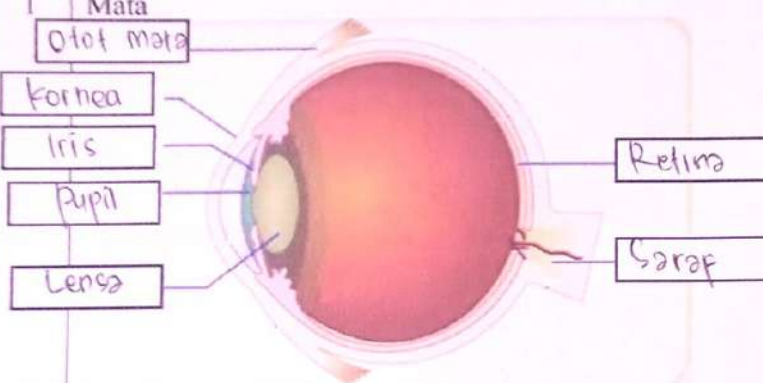
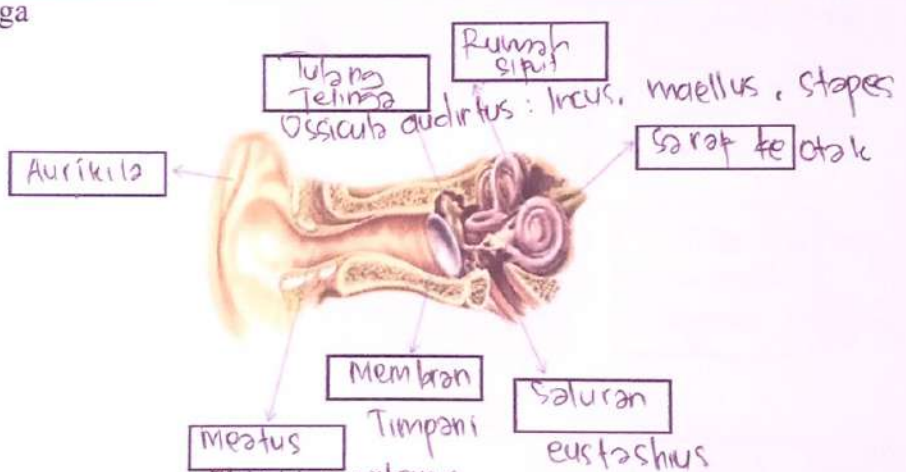



WORKSHEETS (LEMBAR KERJA)

| | |
|--------------------|------------------------------------|
| Mata Kuliah | : Anatomi |
| Materi | : Anatomi Panca Indra |
| NIM>Nama Mahasiswa | : 2110101016 (Cici. Pamesti. Dewi) |

| No | Keterangan | Pembahasan |
|----|------------|------------|
|----|------------|------------|

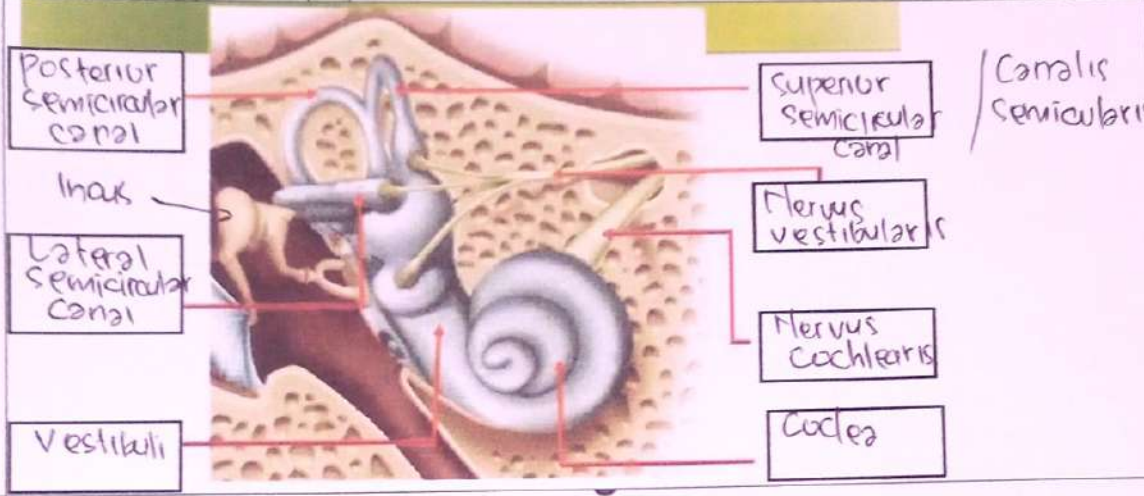
| | | |
|---|--|---|
| 1 | <p>Mata</p> <p>Otot mata</p> <p>Kornea</p> <p>Iris</p> <p>Pupil</p> <p>Lensa</p> |  <p>Retina</p> <p>Saraf</p> |
|---|--|---|

| | | |
|--|----------------|--|
| | <p>Telinga</p> |  <p>Aurikula</p> <p>Meatus Acusticus externus</p> <p>Membran Timpani</p> <p>Saluran eustachius</p> <p>Rumpus sipit</p> <p>Ossicula auditus: Incus, malleus, stapes</p> <p>Saraf ke otak</p> |
|--|----------------|--|

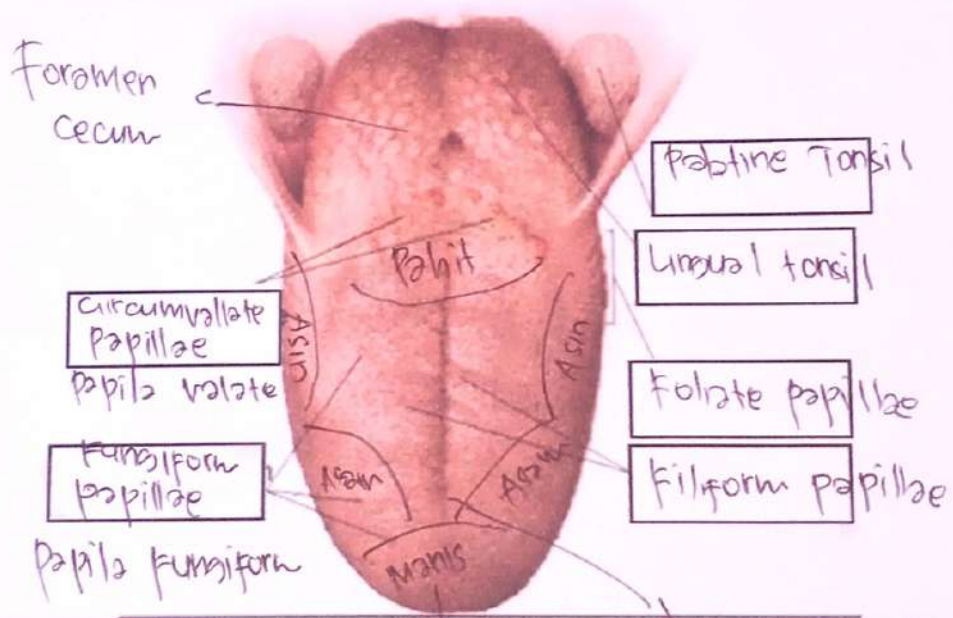
| | | |
|--|---|--|
| | <p>Helix</p> <p>Scapha</p> <p>antihelix</p> <p>Konalis auditorius eksterna</p> <p>Auricularis</p> |  <p>Tubang kulit preaurikuler</p> <p>Skin tag preaurikuler</p> <p>Tragus</p> <p>Insicura intertragica</p> |
|--|---|--|

| No | Keterangan | Pembahasan |
|----|------------|------------|
|----|------------|------------|

Canalis Semicircularis



Foramen Cecum



Apex lingualis

Sulcus mediani lingue