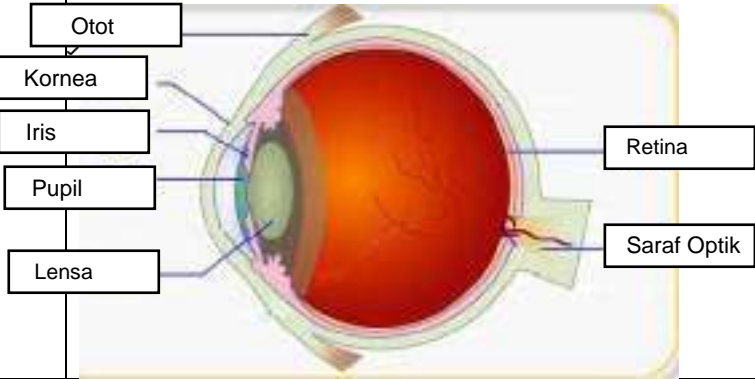
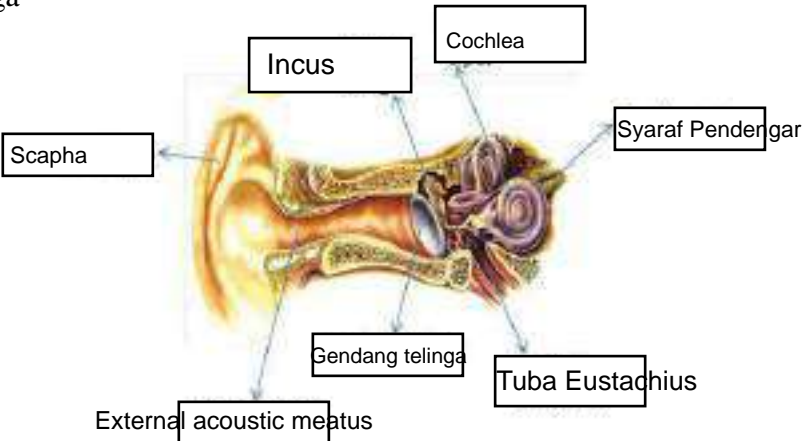
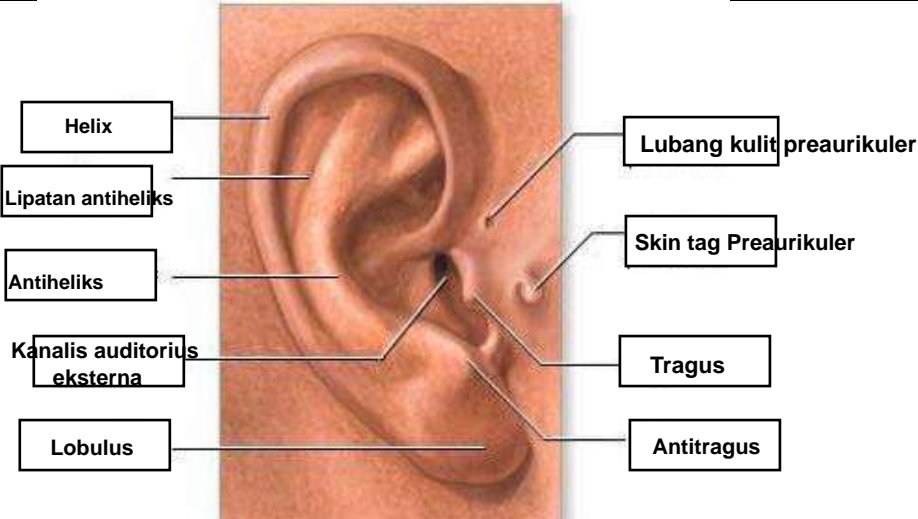

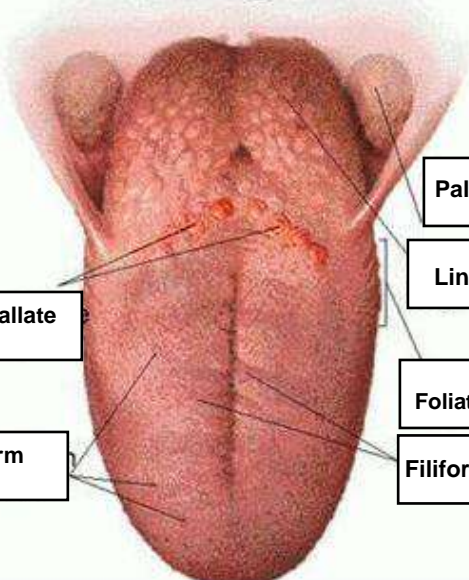


**WORKSHEETS (LEMBAR KERJA)**

<b>Mata Kuliah</b>	: <b>Anatomi</b>
<b>Materi</b>	: <b>Anatomi Panca Indra</b>
<b>NIM&gt;Nama Mahasiswa</b>	: 2110101056 / Aliya Puspita Rizwani

No	Keterangan	Pembahasan
1	<p>Mata</p> 	
	<p>Telinga</p> 	
		

No	Keterangan	Pembahasan
	<p data-bbox="295 331 454 409">Senicircular Canals</p> <p data-bbox="295 495 454 573">Senicircular Canals</p> <p data-bbox="295 658 454 736">Vestibular Apparatus</p>	 <p data-bbox="1002 331 1161 409">Senicircular Canals</p> <p data-bbox="1002 450 1161 528">Vestibular Nerve</p> <p data-bbox="1002 568 1161 647">Cochlear Nerve</p> <p data-bbox="1002 658 1161 736">Cochlea</p>
	<p data-bbox="475 1037 671 1115">Circumvallate Papillae</p> <p data-bbox="475 1178 660 1256">Fungiform Papillae</p>	 <p data-bbox="1018 909 1211 987">Palatine Tonsil</p> <p data-bbox="1018 999 1195 1077">Lingual Tonsil</p> <p data-bbox="1018 1111 1187 1189">Foliate Papillae</p> <p data-bbox="1018 1200 1187 1279">Filiform Papillae</p>