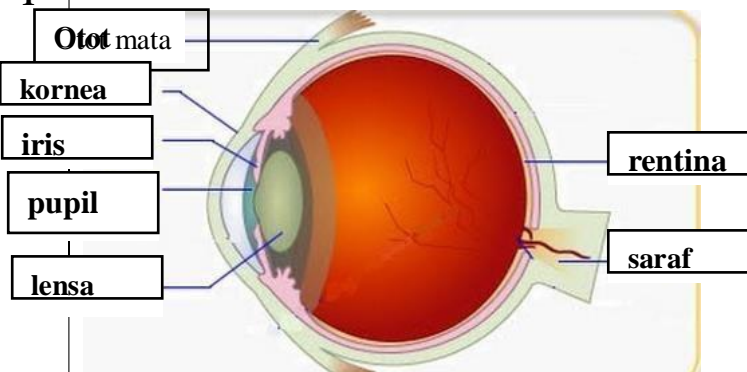



WORKSHEETS (LEMBAR KERJA)


Mata Kuliah	: Anatomi
Materi	: Anatomi Panca Indra
NIM>Nama Mahasiswa	: 2110101037 / DINA BELA SETIAWATI


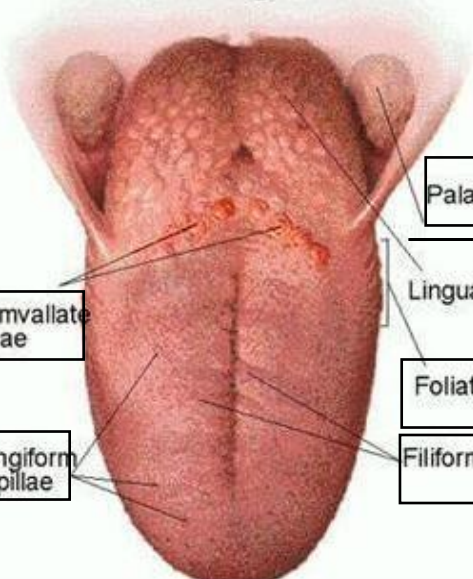
No	Keterangan	Pembahasan
----	------------	------------

1	<p>Otot mata</p> <p>kornea</p> <p>iris</p> <p>pupil</p> <p>lensa</p>	
---	---	---

Telinga

<p>Daun telinga</p> <p>Lubang telinga</p>		<p>Rumah siput</p> <p>Saraf ke otak</p> <p>Saluran eustashius</p>
---	---	---

<p>Heliks</p> <p>Lipatan antiheliks</p> <p>Antiheliks</p> <p>analis auditorius eksterna</p> <p>Lobulus</p>		<p>Lubang kulit preaurikuler</p> <p>Skin tag preaurikuler</p> <p>Tragus</p> <p>Antitragus</p>
--	---	---

No	Keterangan	Pembahasan
	<p>Posterior semicircular canal</p> <p>Lateral semicircular canal</p> <p>Vestibuli</p>	 <p>Superior semicircular canal</p> <p>Nervus Vestibularis</p> <p>Nervus Cochlearis</p> <p>Cochlea</p>
		 <p>Palatine Tonsil</p> <p>Lingual Tonsil</p> <p>Foliate Papillae</p> <p>Filiform Papillae</p> <p>Fungiform Papillae</p> <p>Circumvallate Papillae</p>