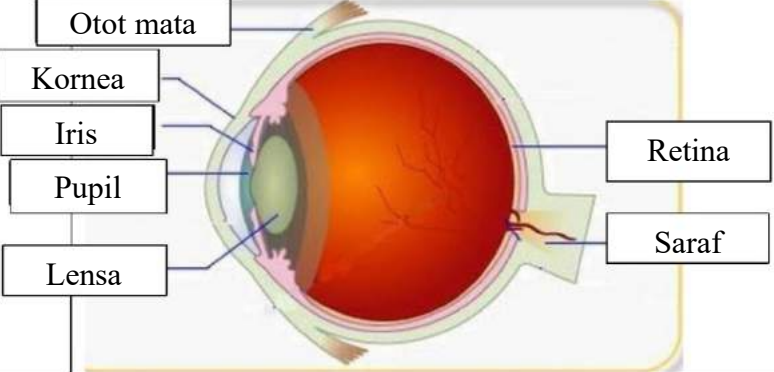

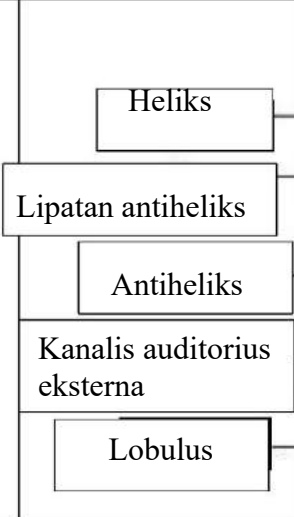
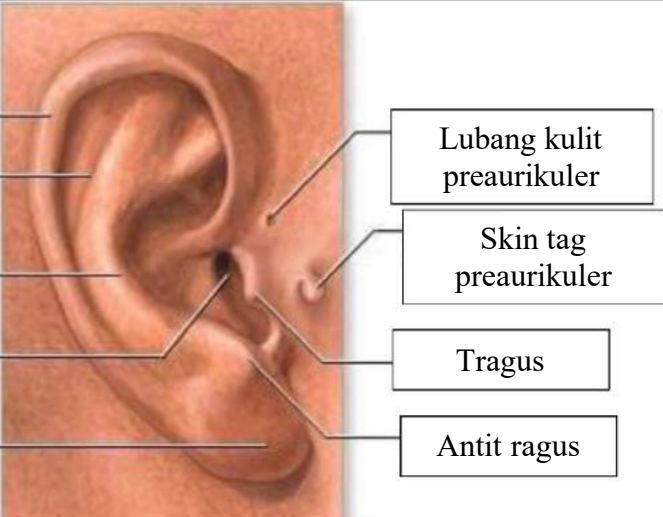

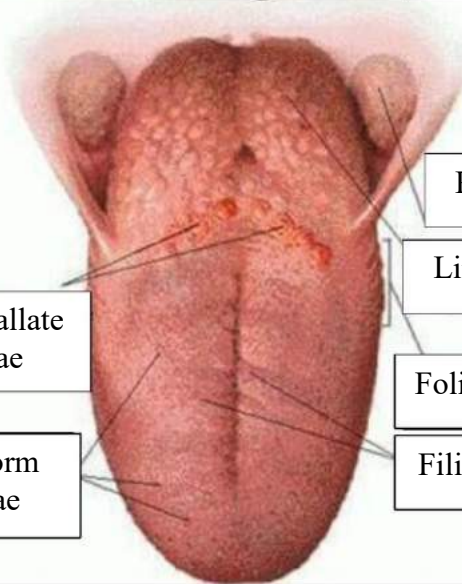


WORKSHEETS (LEMBAR KERJA)

Mata Kuliah	: Anatomi
Materi	: Anatomi Panca Indra
NIM>Nama Mahasiswa	: 2110101042/Suci Wulandari

No	Keterangan	Pembahasan
1	<p>Mata</p> 	
	<p>Telinga</p> 	
		

No	Keterangan	Pembahasan
	<p>Semicircular</p> <p>Semicircular duct lateral</p> <p>Vestibuli</p>	 <p>Semicircular duct anterior</p> <p>Vestibular nerve</p> <p>Cochlea nerve</p> <p>Cochlea</p>
	<p>Circumvallate papillae</p> <p>Fungiform papillae</p>	 <p>Palatine tonsil</p> <p>Lingual tonsil</p> <p>Foliate papillae</p> <p>Filiform papillae</p>