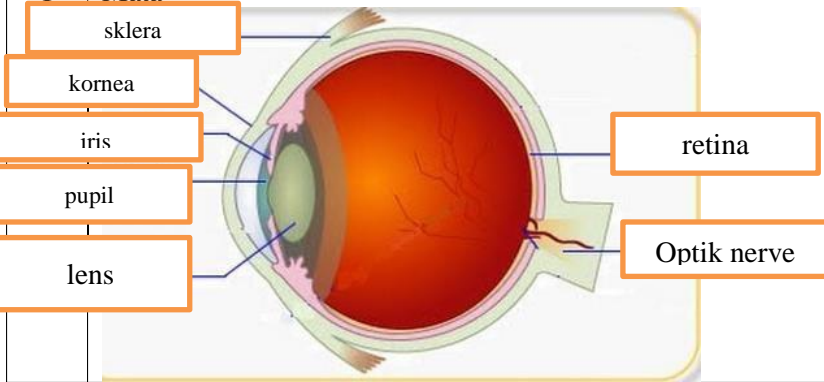
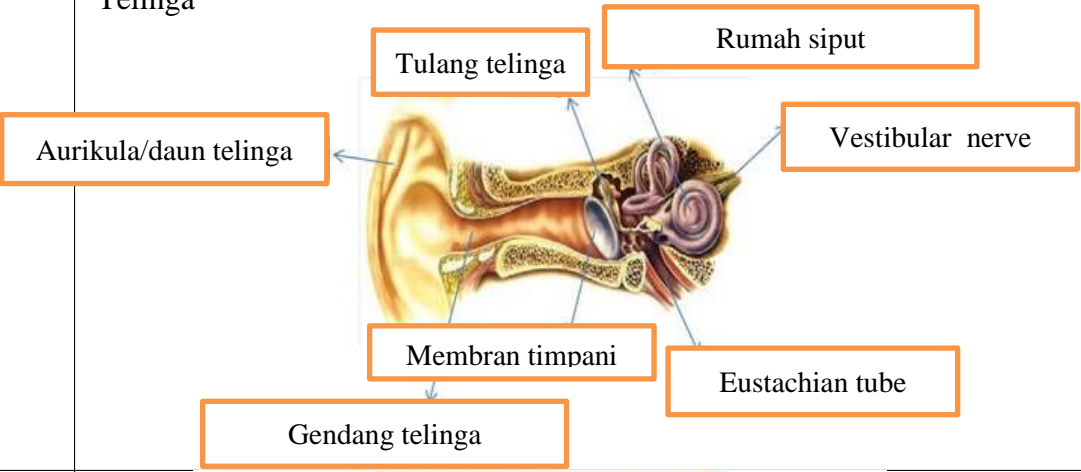
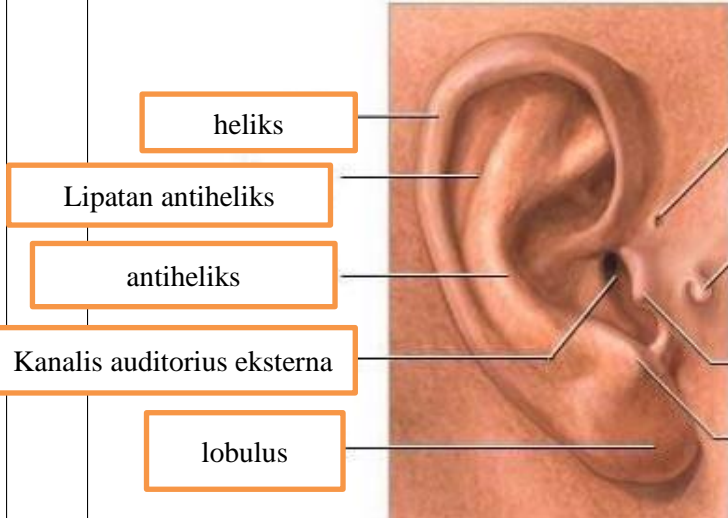
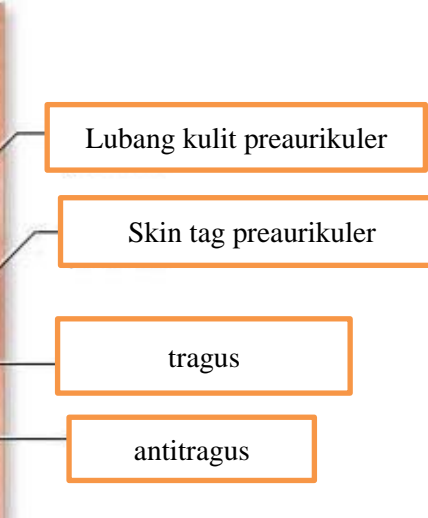
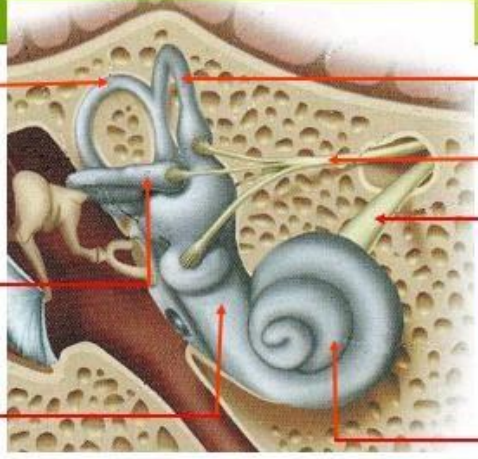
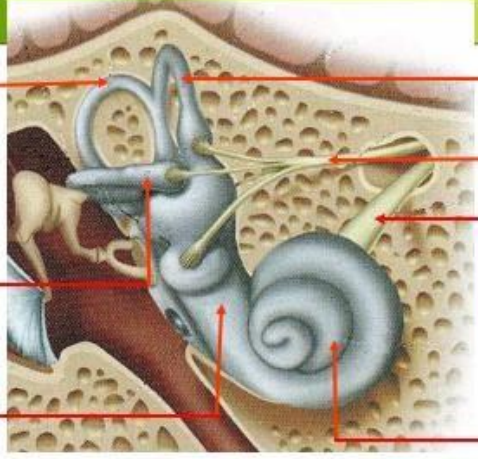
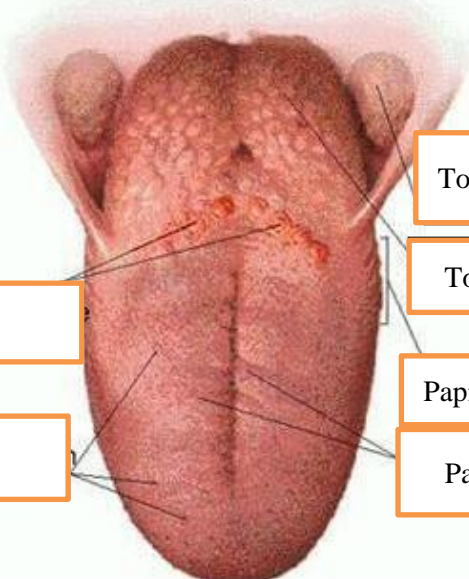
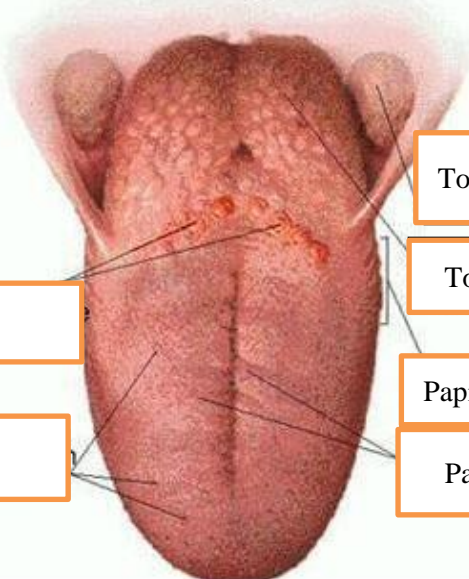


WORKSHEETS (LEMBAR KERJA)

Mata Kuliah	: Anatomi
Materi	: Anatomi Panca Indra
NIM>Nama Mahasiswa	: 2110101066/areta maurindha pratiwi

No	Keterangan	Pembahasan
1	<p>Mata</p> 	
	<p>Telinga</p> 	
		

No	Keterangan	Pembahasan
	 <p data-bbox="193 315 459 405">Posterior semicircular canal</p> <p data-bbox="233 461 459 595">Lateral semicircular canal</p> <p data-bbox="233 651 459 734">Vestibular complex</p>	 <p data-bbox="991 304 1270 394">Superior semicircular canal</p> <p data-bbox="983 450 1278 517">Saraf vestibular/</p> <p data-bbox="983 551 1278 640">Saraf ruang siput/cochlear nerve</p> <p data-bbox="991 663 1318 730">Ruang siput/cochlea</p>
	 <p data-bbox="217 1021 671 1099">Papila Circumvalate</p> <p data-bbox="288 1155 663 1234">Papila fungiformis</p>	 <p data-bbox="1007 875 1270 954">Tonsila paltina</p> <p data-bbox="1007 987 1270 1055">Tonsila linguanis</p> <p data-bbox="991 1099 1262 1167">Papila foliate</p> <p data-bbox="991 1178 1270 1256">Papila liliformis</p>