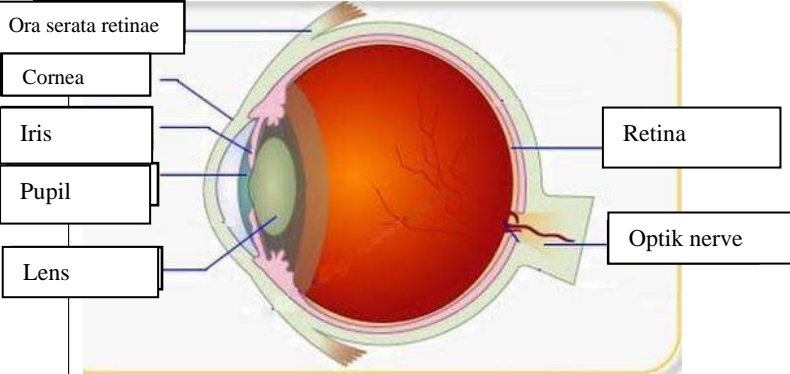
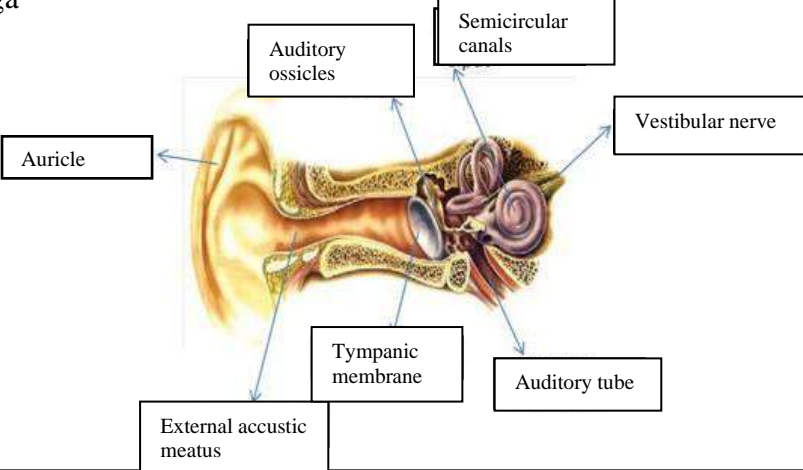
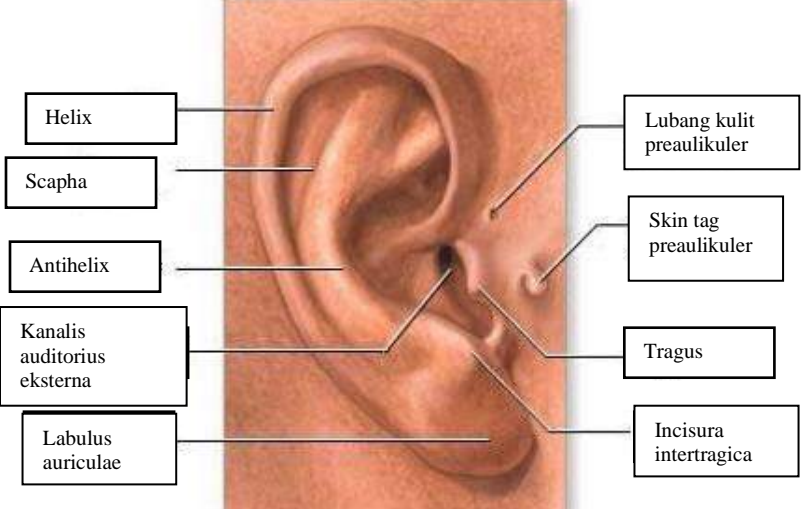
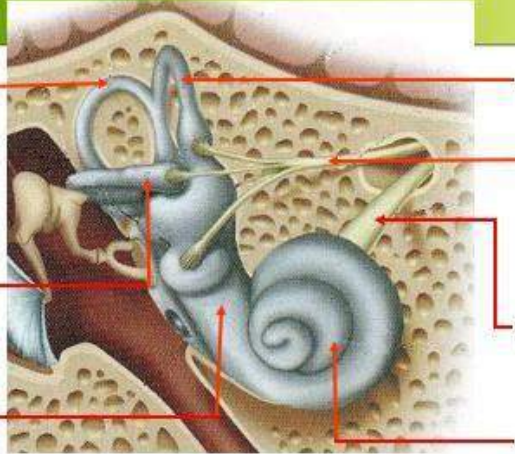
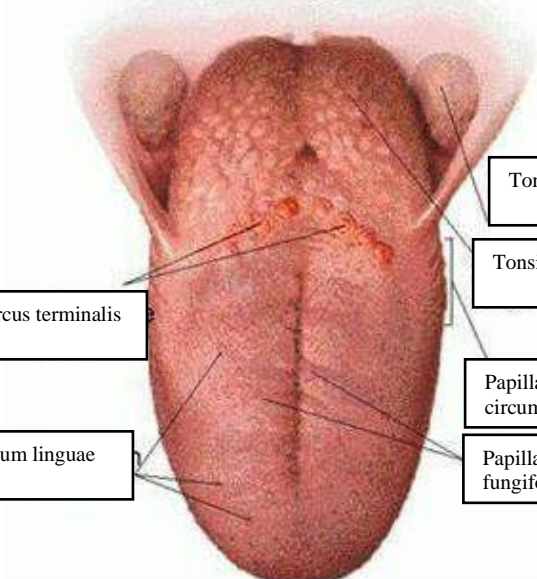


**WORKSHEETS (LEMBAR KERJA)**

<b>Mata Kuliah</b>	<b>: Anatomi</b>
<b>Materi</b>	<b>: Anatomi Panca Indra</b>
<b>NIM&gt;Nama Mahasiswa</b>	<b>: 2110101041/DWI YANTI</b>

No	Keterangan	Pembahasan
1	<p><b>Mata</b></p> 	
	<p><b>Telंगा</b></p> 	
		

No	Keterangan	Pembahasan
	<p>Semicircular canals posterior</p> <p>Cristae within ampullae</p> <p>Vestibular complex</p>	 <p>Semicircular canals anterior</p> <p>Vestibular branch</p> <p>Cochlear branch</p> <p>Cochlea</p>
	<p>Surcus terminalis</p> <p>Dorsum linguae</p>	 <p>Tonsila palatina</p> <p>Tonsila lingualis</p> <p>Papilla circumvalate</p> <p>Papilla fungiformis</p>