

WORKSHEETS (LEMBAR KERJA)

Mata Kuliah	: Anatomi
Materi	: Anatomi Panca Indra
NIM>Nama Mahasiswa	: 2110101038 / Baita Awiktamara Nisa.

No	Keterangan	Pembahasan
----	------------	------------

1 Mata

Otot mata.

Kornea

Iris

Pupil

Lensa

Retina

Saraf

Telinga

Daun telinga.

Tulang Pen-
dengaran
(Audi-
otory bones).

Cochlea

Saraf ke
Otak.

Gendang
telinga
(eardrum).

Saluran telinga
(ear canal).

Tube
Eustachius.

Heliks.

Lipatan antiheliks.

Anti heliks.

Analis auditorius ekstern al



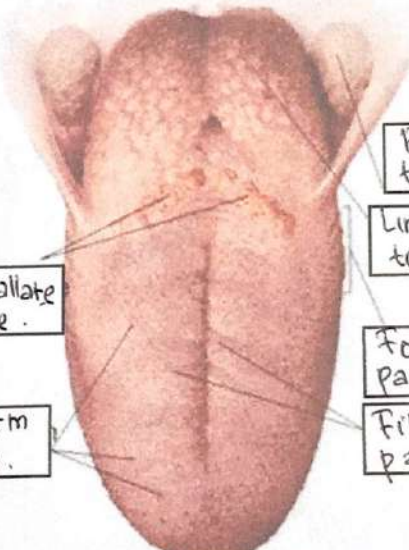
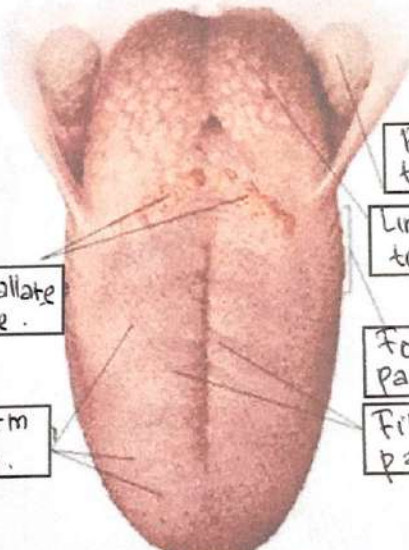
Lobulus

Lubang kuli Preaurikuler.

Skin tag preaurikuler.

Tragus

Antitragus.

No	Keterangan	Pembahasan
	 <p>Posterior Semicircular Canal.</p> <p>Lateral Semicircular Canal.</p> <p>Vestibuli</p>	 <p>Superior Semicircular Canal.</p> <p>Nervus Vestibularis.</p> <p>Nervus Cochlearis.</p> <p>Cochlea.</p>
	 <p>Circumvallate Papillae.</p> <p>Fungiform Papillae.</p>	 <p>Palatine tonsil.</p> <p>Lingual tonsil.</p> <p>Foliate papillae.</p> <p>Filiform papillae.</p>