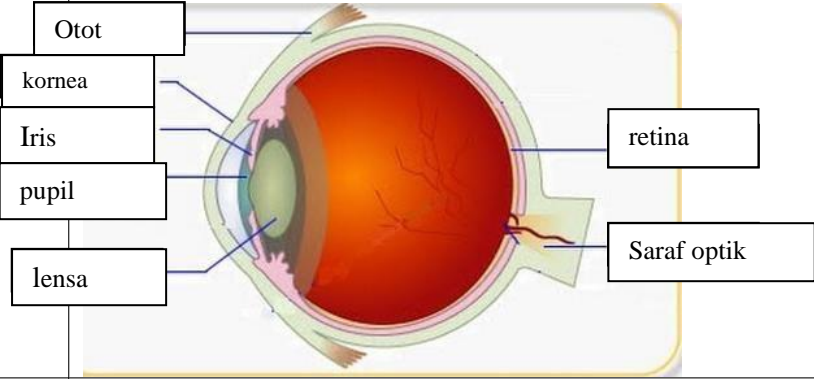
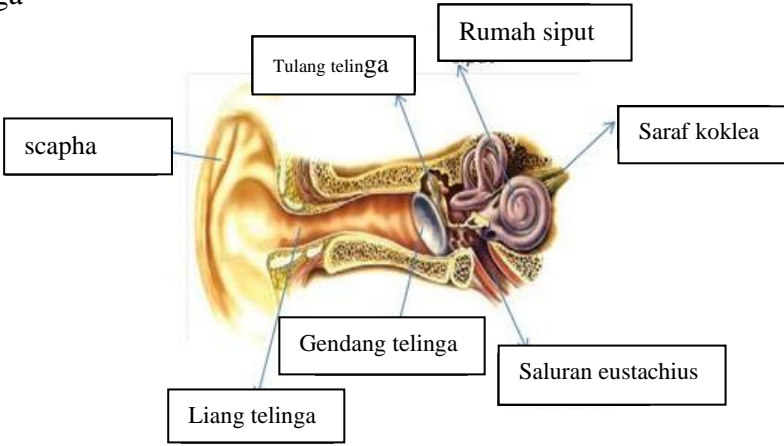
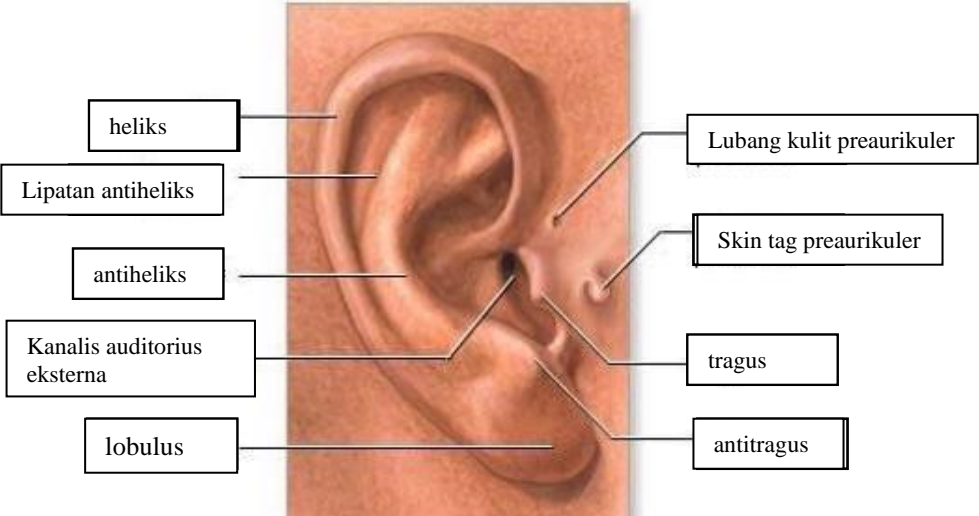
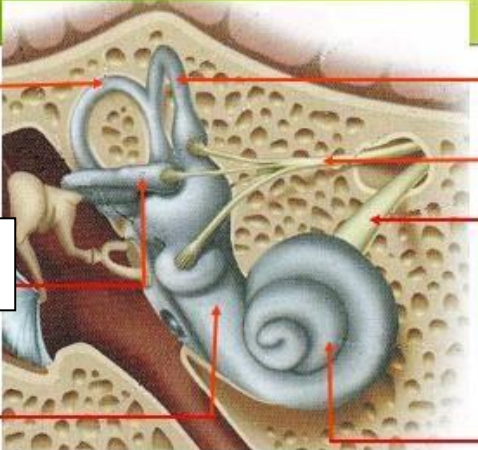
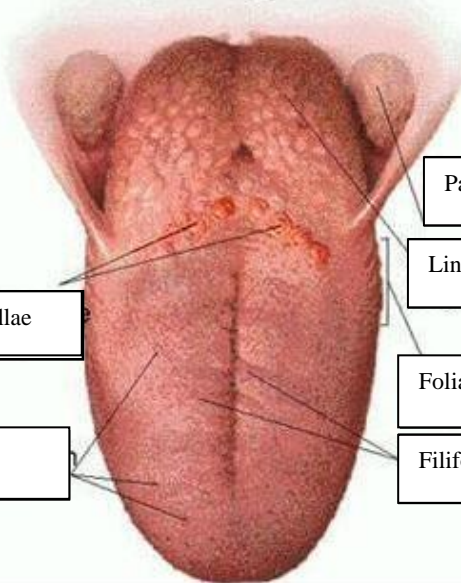


**WORKSHEETS (LEMBAR KERJA)**

<b>Mata Kuliah</b>	: <b>Anatomi</b>
<b>Materi</b>	: <b>Anatomi Panca Indra</b>
<b>NIM&gt;Nama Mahasiswa</b>	: 2110101032 / Izza syifa wahyu Salfaira

No	Keterangan	Pembahasan
1	<p>Mata</p> 	
	<p>Telinga</p> 	
		

No	Keterangan	Pembahasan
	<p data-bbox="304 327 448 405">Semi circular canal</p> <p data-bbox="304 495 448 573">Lateral semi circular canal</p> <p data-bbox="304 663 448 719">vestibuli</p>	 <p data-bbox="1007 327 1182 405">Semi circular canal</p> <p data-bbox="1007 450 1246 506">Nervus vestibularis</p> <p data-bbox="1007 573 1246 629">Nervus cochlearis</p> <p data-bbox="1007 663 1150 719">koklea</p>
	<p data-bbox="384 1032 671 1088">Circumvallate papillae</p> <p data-bbox="384 1178 655 1234">Fungiform papillae</p>	 <p data-bbox="1007 898 1198 954">Palatine tonsil</p> <p data-bbox="1007 987 1198 1043">Lingual tonsil</p> <p data-bbox="1007 1099 1262 1155">Foliate papilla papillae</p> <p data-bbox="1007 1178 1214 1234">Filiform papillae</p>