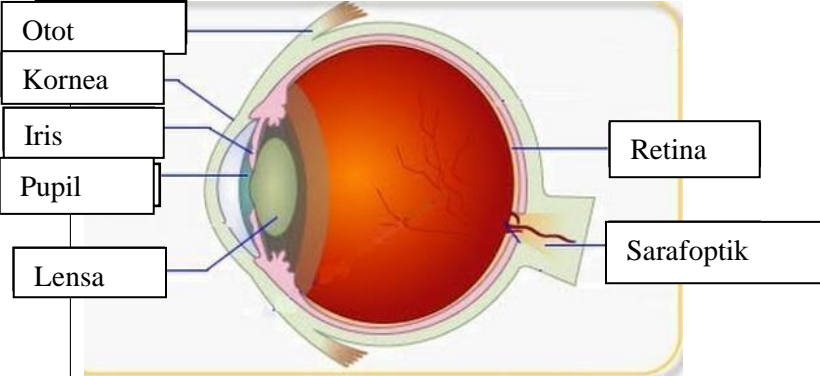
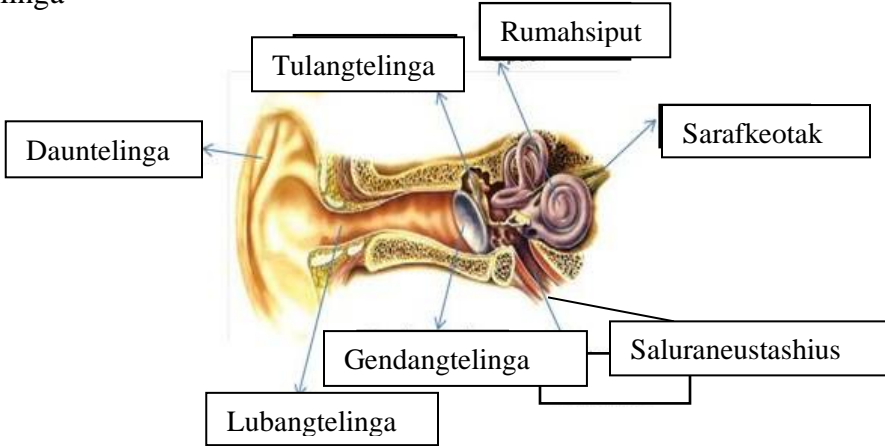
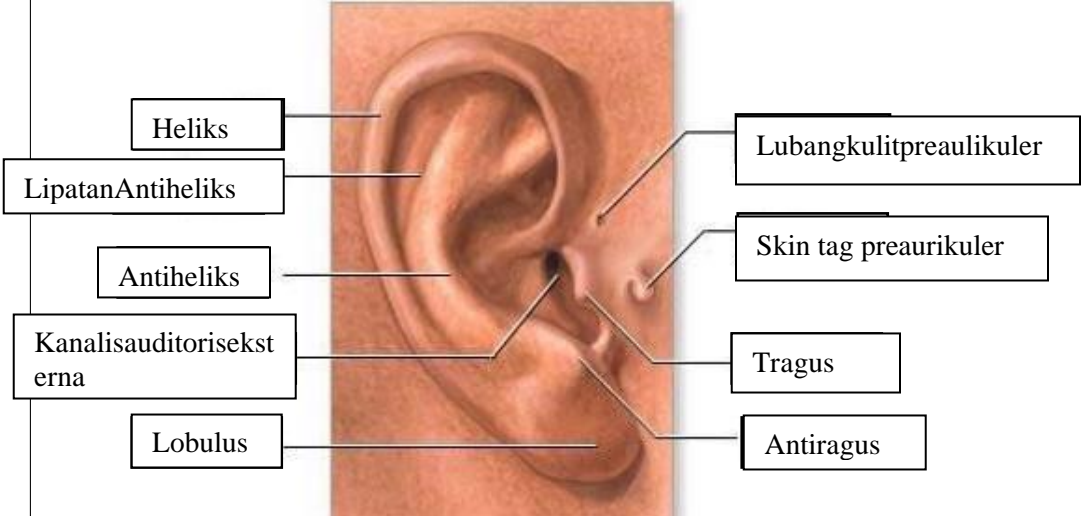


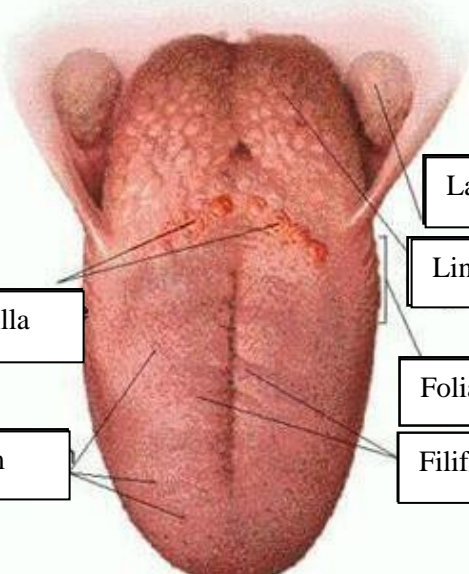
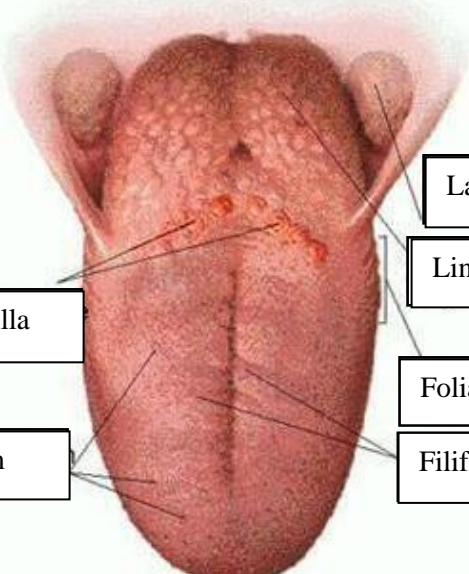


**WORKSHEETS (LEMBAR KERJA)**

<b>Mata Kuliah</b>	: <b>Anatomi</b>
<b>Materi</b>	: <b>Anatomi Panca Indra</b>
<b>NIM&gt;Nama Mahasiswa</b>	: <b>2110101055/Niken Desri Fauzana</b>

No	Keterangan	Pembahasan
1	Mata	 <p>Diagram of the human eye showing internal structures. Labels on the left: Otot, Kornea, Iris, Pupil, Lensa. Labels on the right: Retina, Sarafoptik.</p>
	Telinga	 <p>Diagram of the middle ear showing ossicles and other structures. Labels: Tulangtelinga, Rumahsiput, Sarafkeotak, Dauntelinga, Gendangtelinga, Saluraneustashius, Lubangtelinga.</p>
		 <p>Diagram of the external ear showing its various parts. Labels on the left: Heliks, LipatanAntiheliks, Antiheliks, Kanalis auditoriseksterna, Lobulus. Labels on the right: Lubangkulitpreaulikuler, Skin tag preaurikuler, Tragus, Antiragus.</p>

No	Keterangan	Pembahasan
	 <p data-bbox="268 315 475 432">Semicircular Canals</p> <p data-bbox="248 488 456 577">Vestibular complex</p> <p data-bbox="225 651 456 719">Tingkapondar</p>	 <p data-bbox="1002 327 1329 416">Semicircular duct within anterior semicircular</p> <p data-bbox="1002 443 1294 566">1. Malleus 2. Incus 3. Stapes</p> <p data-bbox="1002 584 1209 640">Saraf kolesera</p> <p data-bbox="1002 663 1326 719">Kolek (rumah sipit)</p>
	 <p data-bbox="344 1032 671 1099">Circumvallate papilla</p> <p data-bbox="384 1178 663 1234">Papil fungiform</p>	 <p data-bbox="1015 898 1382 965">Langit-langit tenggorokan</p> <p data-bbox="1007 987 1238 1043">Lingual tonsil</p> <p data-bbox="991 1099 1254 1155">Foliate papillae</p> <p data-bbox="991 1178 1238 1234">Filiform papillae</p>