

WORKSHEETS (LEMBAR KERJA)

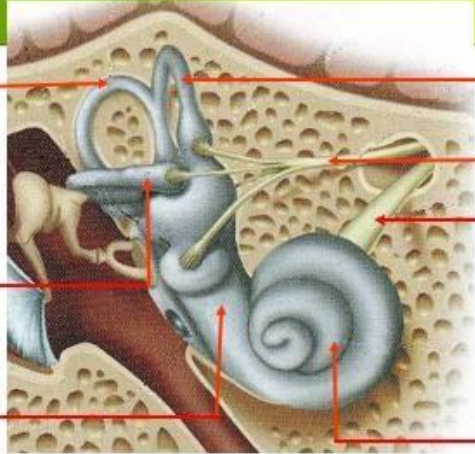
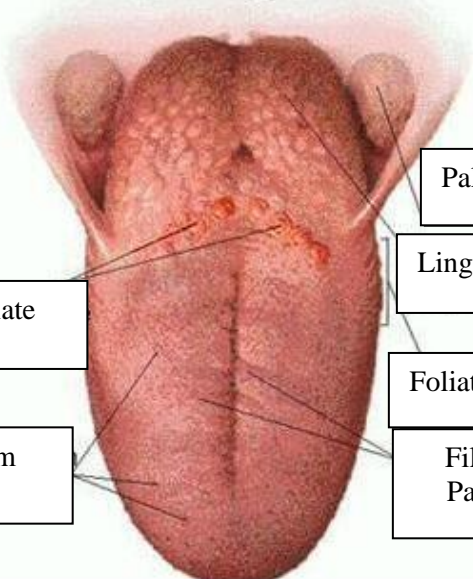
| | |
|------------------------------|--|
| Mata Kuliah | : Anatomi |
| Materi | : Anatomi Panca Indra |
| NIM>Nama Mahasiswa | : Rizfi Pramesi Lalita Fasya/2110101065 |

| No | Keterangan | Pembahasan |
|----|------------|------------|
|----|------------|------------|

| | | |
|---|------|---|
| 1 | Mata | <p>An anatomical diagram of the human eye in cross-section. Labels on the left side include: Otot mata (eye muscle), Kornea (cornea), Iris, Pupil, and Lensa (lens). Labels on the right side include: Retina and Syaraf (nerve).</p> |
|---|------|---|

| | |
|---------|--|
| Telinga | <p>An anatomical diagram of the middle ear. Labels include: Tulang Pendengaran/Auditory Ossicles, Semicircular Canals, Syaraf Pendengaran (auditory nerve), Tympanic Membrane (Ear Drum), Tuba Eustachius (Eustachian tube), External Acoustic Meatus (Ear Canal), and Auricula (outer ear).</p> |
|---------|--|

| | | |
|---|--|--|
| <p>Helix</p> <p>Scapha</p> <p>Antihelix</p> <p>Concha</p> <p>Auricular Lobule (Earlobe)</p> | <p>A photograph of a human ear with labels: Helix, Scapha, Antihelix, Concha, Auricular Lobule (Earlobe), Tragus, and Insicura Intertragica.</p> | <p>[Empty box]</p> <p>[Empty box]</p> <p>Tragus</p> <p>Insicura Intertragica</p> |
|---|--|--|

| No | Keterangan | Pembahasan |
|----|---|---|
| | <p>Posterior Canal</p> <p>Horizontal Canal</p> <p>Saccule</p> |  <p>Superior Canal</p> <p>Syaraf Vestibular</p> <p>Syaraf Ruang Siput</p> <p>Cochlea</p> |
| | <p>Circumvallate Papillae</p> <p>Fungiform Papillae</p> |  <p>Palatine Tonsil</p> <p>Lingual Tonsil</p> <p>Foliate Papillae</p> <p>Filiform Papillae</p> |