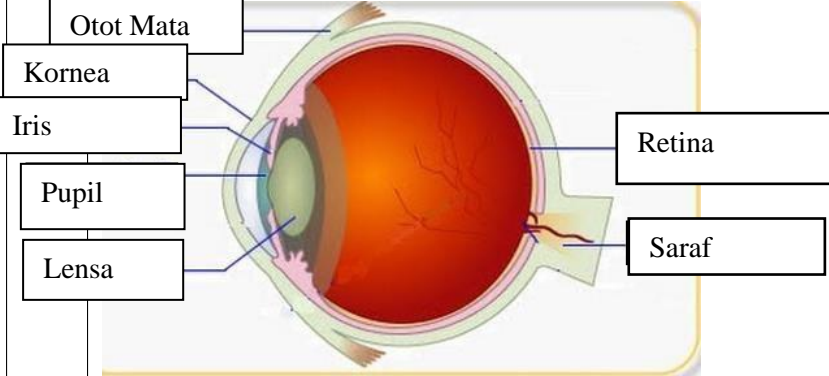
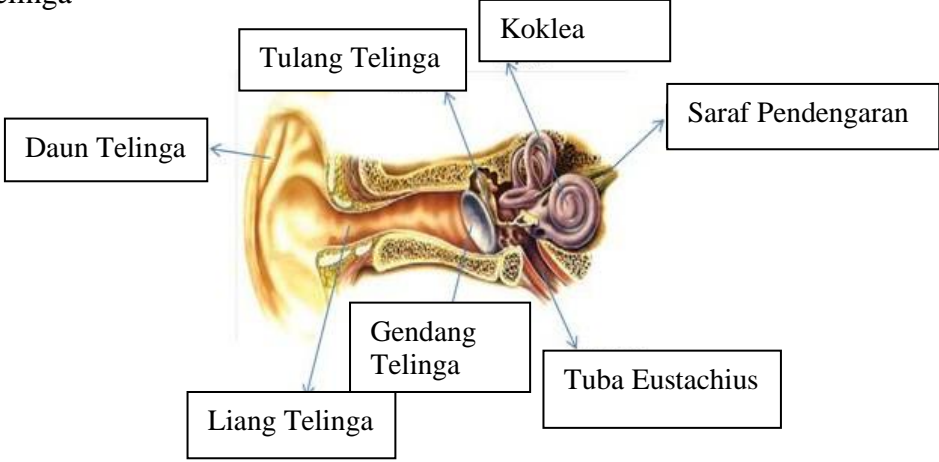
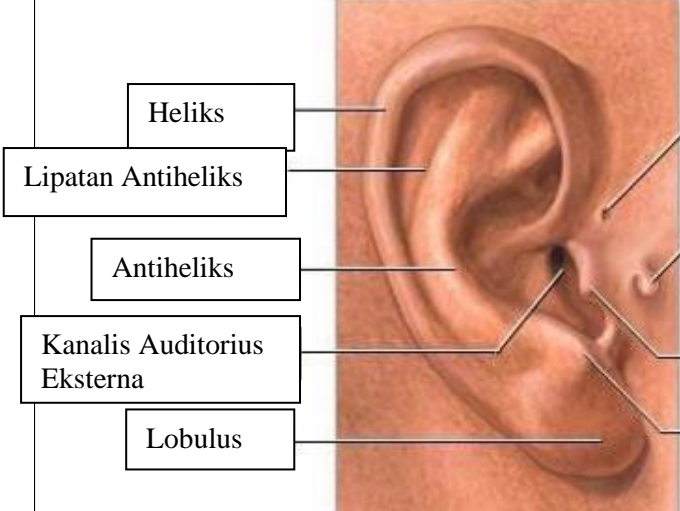
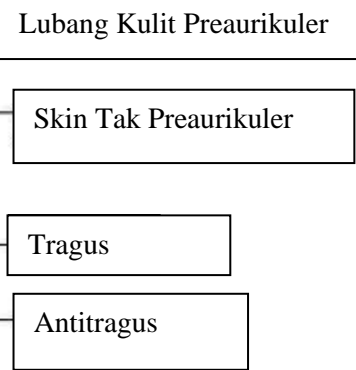
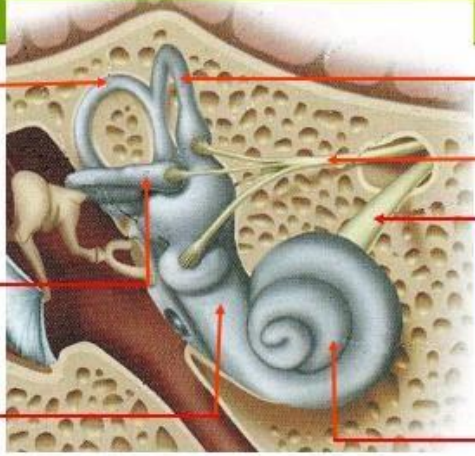
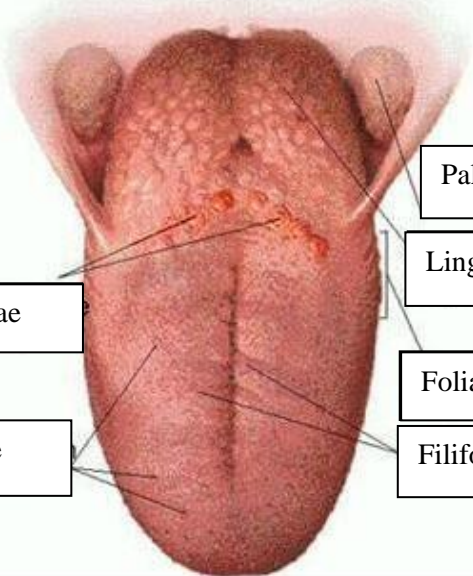


**WORKSHEETS (LEMBAR KERJA)**

<b>Mata Kuliah</b>	: Anatomi
<b>Materi</b>	: Anatomi Panca Indra
<b>NIM&gt;Nama Mahasiswa</b>	: 2110101062/Katrin Septia Rini

No	Keterangan	Pembahasan
1	<p>Mata</p> 	
	<p>Telinga</p> 	
		

No	Keterangan	Pembahasan
	<p data-bbox="256 315 459 405">Semicircular</p> <p data-bbox="220 479 459 584">Vestibular Complex</p> <p data-bbox="225 658 459 725">Round Window</p>	 <p data-bbox="1002 331 1350 412">Semicircular canals within the anterior semicircular</p> <p data-bbox="991 443 1235 562">1. Malleus 2. Incus 3. Stapes</p> <p data-bbox="991 573 1251 636">Auditory Nerve</p> <p data-bbox="1002 663 1161 725">Cochlea</p>
	<p data-bbox="320 1032 671 1099">Circumvallate Papillae</p> <p data-bbox="341 1173 660 1240">Fungiform Papillae</p>	 <p data-bbox="1007 898 1302 965">Palatine Tonsil</p> <p data-bbox="1007 987 1262 1055">Lingual Tonsil</p> <p data-bbox="991 1099 1267 1167">Foliate Papillae</p> <p data-bbox="991 1178 1267 1245">Filiform Papillae</p>