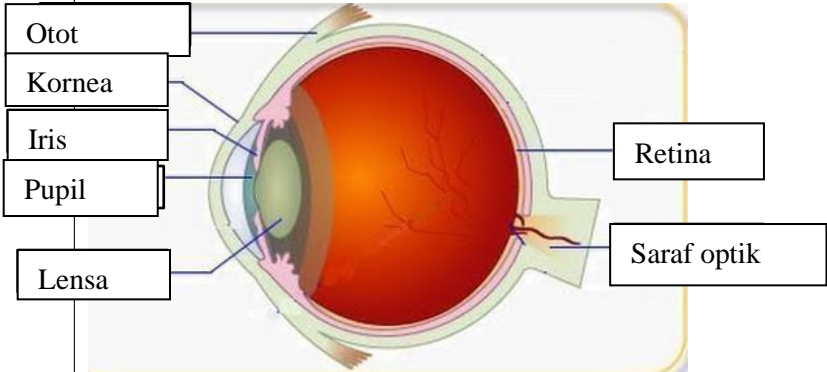
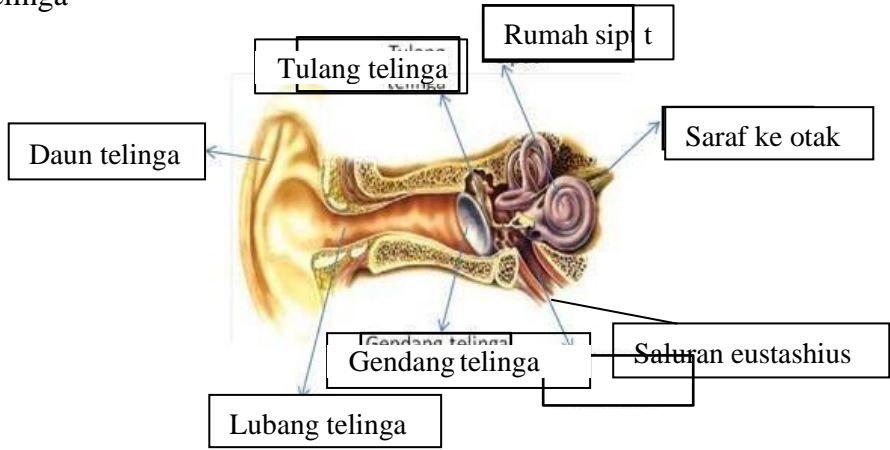
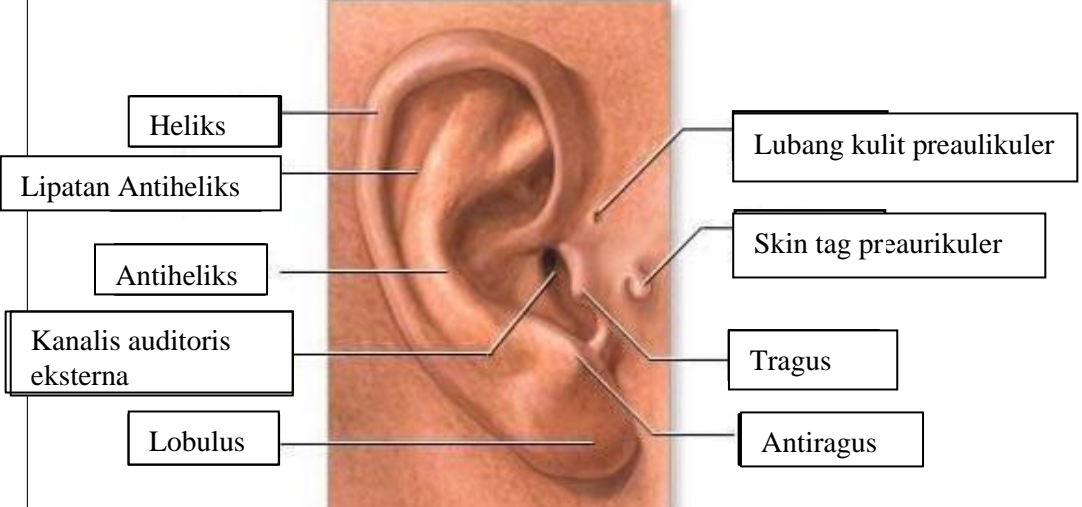
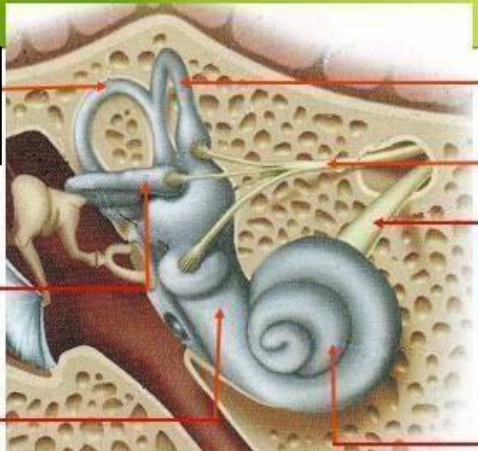
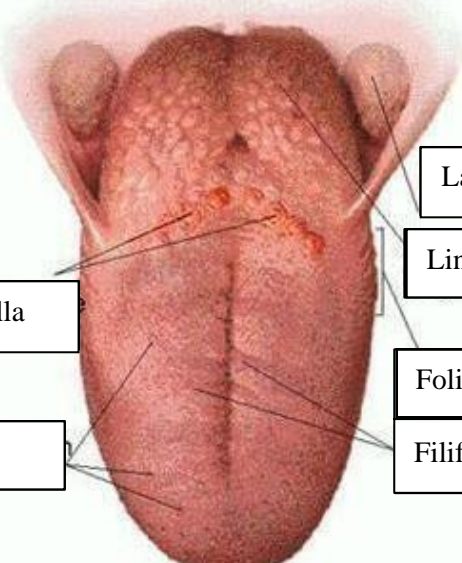


WORKSHEETS (LEMBAR KERJA)

Mata Kuliah	: Anatomi
Materi	: Anatomi Panca Indra
NIM>Nama Mahasiswa	: 2110101029/Monica Dwi Putri

No	Keterangan	Pembahasan
1	Mata	 <p>Diagram of the human eye showing internal structures. Labels include: Otot (Muscle), Kornea (Cornea), Iris, Pupil, Lensa (Lens), Retina, and Saraf optik (Optic nerve).</p>
	Telinga	 <p>Diagram of the middle ear showing the ossicles and associated structures. Labels include: Daun telinga (Pinna), Tulang telinga (Ear bones), Rumah sipit (Malleus), Saraf ke otak (Nerve to brain), Saluran eustachius (Eustachian tube), Gendang telinga (Tympanic membrane), and Lubang telinga (Ear canal).</p>
		 <p>Diagram of the external ear showing its various parts. Labels include: Heliks (Helix), Lipatan Antiheliks (Antihelical fold), Antiheliks (Antihelix), Kanalis auditoris eksterna (External auditory canal), Lobulus (Lobule), Lubang kulit preaurikuler (Preauricular skin pit), Skin tag preaurikuler (Preauricular skin tag), Tragus, and Antiragus.</p>

No	Keterangan	Pembahasan
	 <p data-bbox="272 315 475 427">Semicircular Canals</p> <p data-bbox="248 488 458 577">Vestibular complex</p> <p data-bbox="225 645 464 719">Tingkap bundar</p>	<p data-bbox="1002 331 1331 421">Semicircular duct within anterior semicor</p> <p data-bbox="994 443 1295 568">1. Malleus 2. Incus 3. Stapes</p> <p data-bbox="1002 584 1211 645">Saraf korea</p> <p data-bbox="1002 663 1326 723">Konklec (rumah siput)</p>
	<p data-bbox="344 1032 675 1099">Circumvallate papilla</p> <p data-bbox="387 1171 663 1238">Papil fungiform</p>	 <p data-bbox="1007 898 1382 965">Langit-langit tenggorokan</p> <p data-bbox="1002 981 1241 1048">Lingual tonsil</p> <p data-bbox="994 1099 1246 1167">Foliate papillae</p> <p data-bbox="994 1182 1246 1249">Filiform papillae</p>