

WORKSHEETS (LEMBAR KERJA)

Mata Kuliah	: Anatomi
Materi	: Anatomi Panca Indra
NIM>Nama Mahasiswa	: 2110101059 / Nur Annisa Ahla

No	Keterangan	Pembahasan
----	------------	------------

1 Mata

Labels on the left side of the eye diagram:

- otot mata
- kornea
- iris
- pupil
- lensa

Labels on the right side of the eye diagram:

- retina
- saraf

Telinga

Labels for the ear diagram:

- Daun telinga
- Tulang pendengar (auditory bones)
- cochlea
- saraf ke otak
- Gendang telinga (tardrum)
- saluran telinga (Ear canal)
- Tube eustachius

Labels for the external ear features:

- Helix
- Uppatan antiheliks
- Antiheliks
- Analis auditorius externa
- Lobulus
- tubang kuni preaurikuler
- skin tag preaurikuler
- Tragus
- Antitragus

No	Keterangan	Pembahasan
----	------------	------------

Posterior
semicircular
Canal

Lateral
semicircular
Canal

Vestibuli

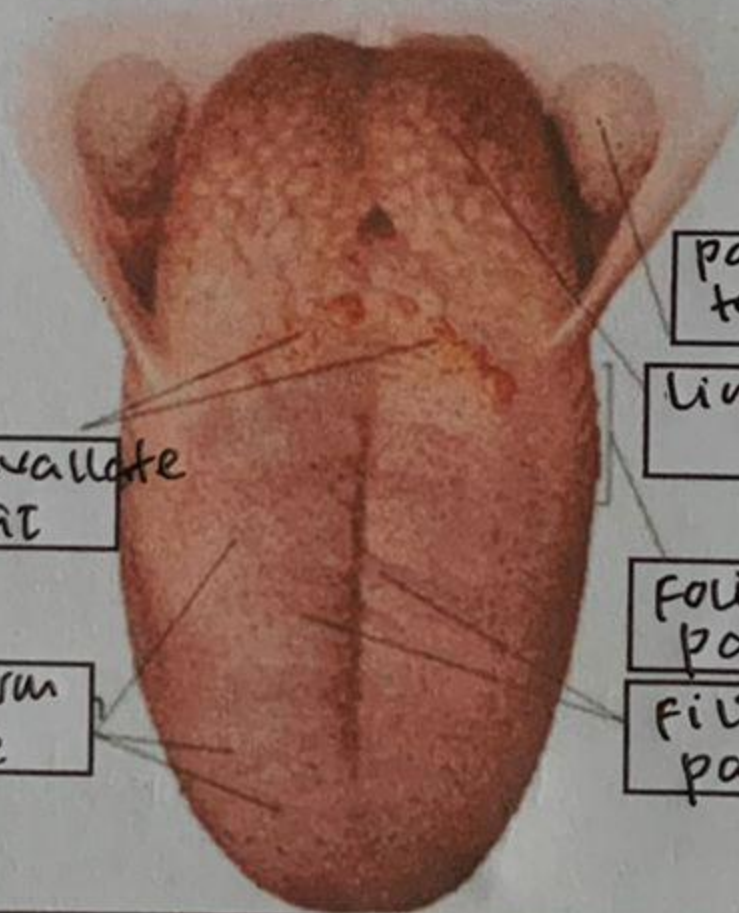


Superior
semicircular
Canal

Nervus
vestibularis

Nervus
tuchlearis

Cochlea



Circumvallate
papillae

Fungiform
papillae

Palatine
Tonsil

Lingual Tonsil

Foliate
papillae

Filiform
papillae