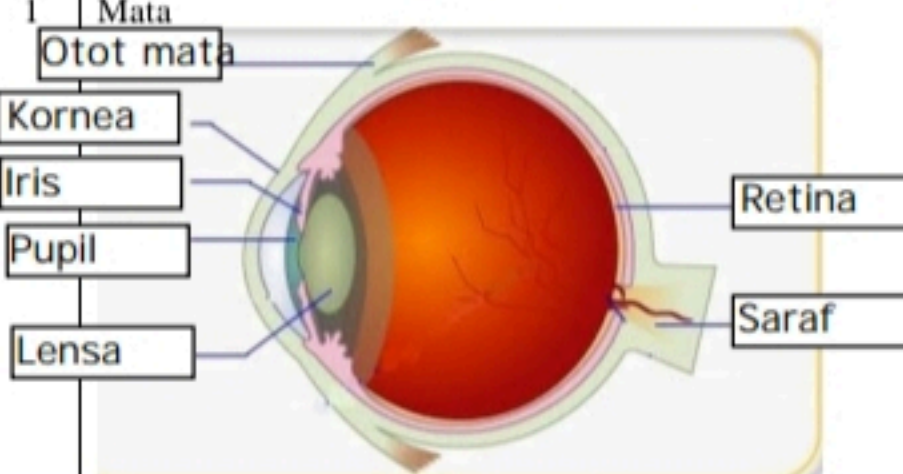

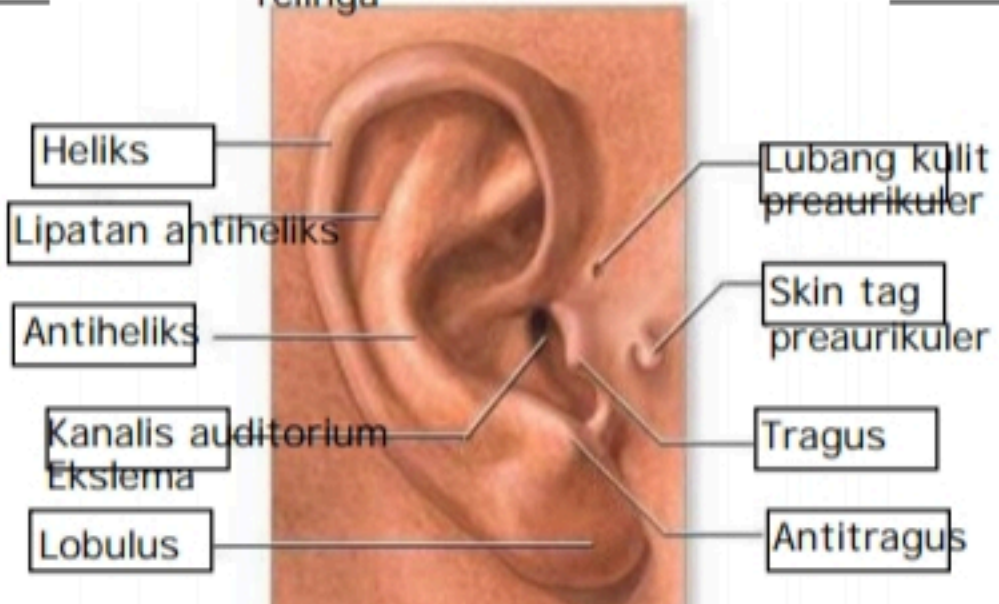
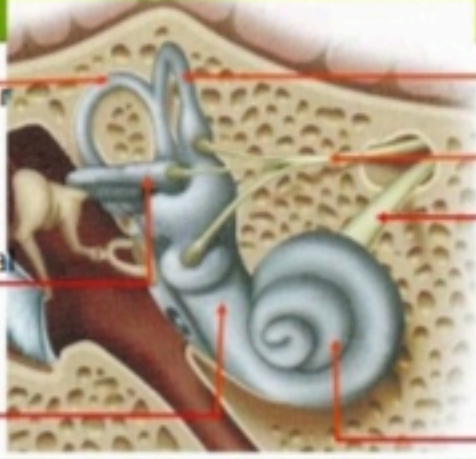
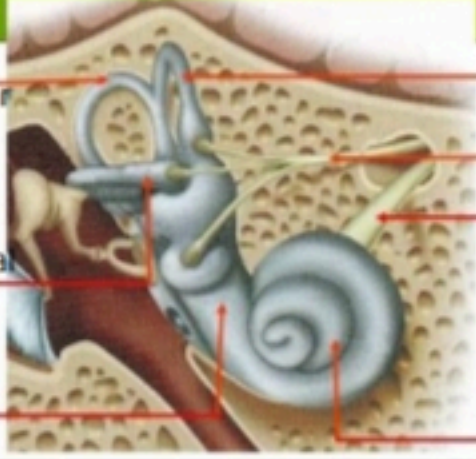
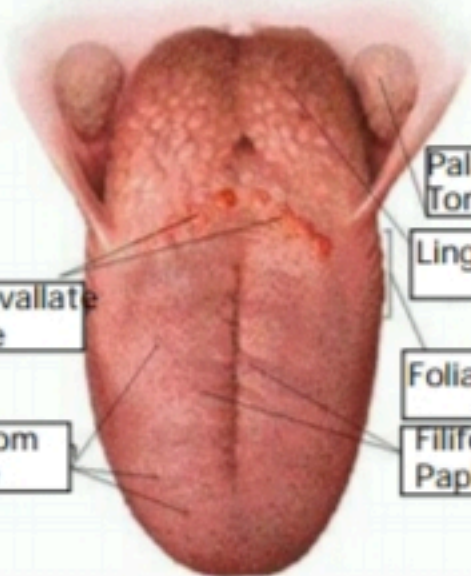
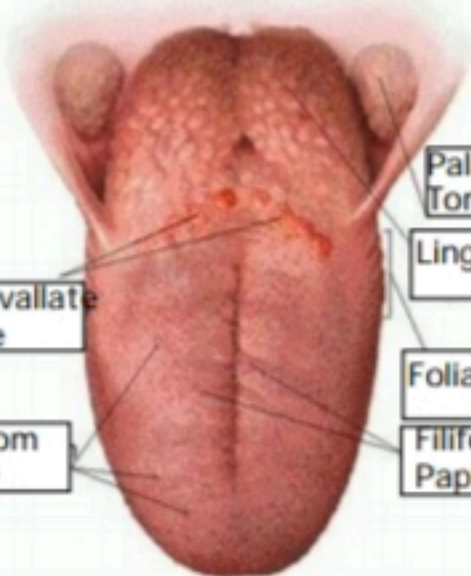


**WORKSHEETS (LEMBAR KERJA)**

<b>Mata Kuliah</b>	: Anatomi
<b>Materi</b>	: Anatomi Panca Indra
<b>NIM&gt;Nama Mahasiswa</b>	: 2110101058/Putri Adelia

No	Keterangan	Pembahasan
1	<p>Mata</p>  <p>Telinga</p> 	
		

No	Keterangan	Pembahasan
	 <p>Posterior Semicircular canal</p> <p>Lateral Semicircular Canal</p> <p>Vestibuli</p>	 <p>Superior Semicircular Canal</p> <p>Nervus vestibularis</p> <p>Nervus cochlearis</p> <p>Cochlea</p>
	 <p>Circumvallate Papillae</p> <p>Fungiform Papillae</p>	 <p>Palatine Tonsil</p> <p>Lingual tonsil</p> <p>Foliate papillae</p> <p>Filiform Papillae</p>