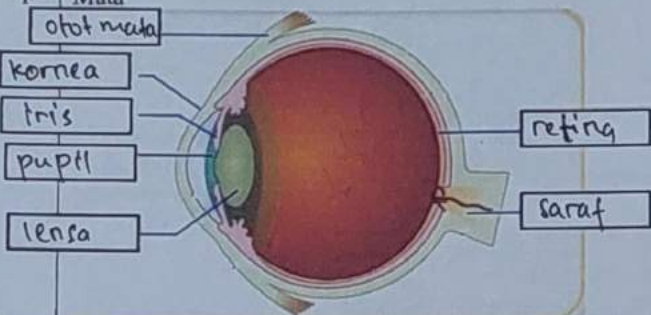

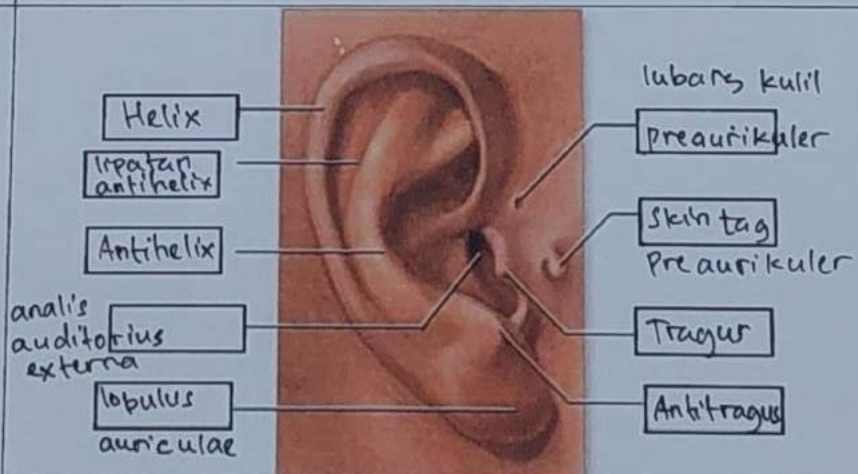


WORKSHEETS (LEMBAR KERJA)

Mata Kuliah	: Anatomi
Materi	: Anatomi Panca Indra
NIM>Nama Mahasiswa	: 2110101030 / Julia Indah Cahyani.

No	Keterangan	Pembahasan
1	Mata	 <p>Diagram of the eye showing internal structures. Labels include: otot mata (eye muscle), kornea (cornea), iris, pupil, lensa (lens), retina, and saraf (nerve).</p>
	Telinga	 <p>Diagram of the ear showing external and internal structures. Labels include: Daun Telinga (ear flap), tulang telinga (ear bones), rumah siput (snail house), saraf ke otak (nerve to brain), gendang telinga (eardrum), saluran eustachius (Eustachian tube), and lubang tel. (ear hole).</p>
		 <p>Diagram of the external ear with detailed labels. On the left: Helix, lipatan antihelix, Antihelix, analis auditorius externa, lobulus auriculae. On the right: lubang kulit preaurikuler, skin tag preaurikuler, Tragus, Antitragus.</p>

No	Keterangan	Pembahasan
----	------------	------------

Posterior		Superior
semicircular canal.		semicircular canal
lateral semicircular canal		nervus vestibularis
vestibuli		nervus cochlearis cochlea

Papillae vallatae	Tonsilla palatina
Papillae fungiformes	Tonsilla lingualis
	papillae foliate
	papillae filiformes