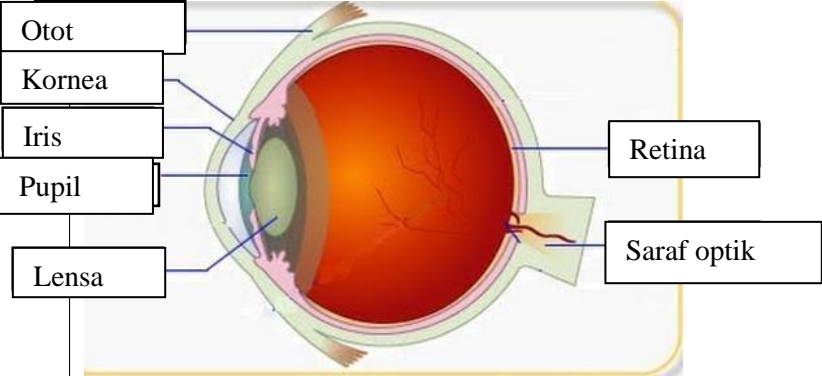
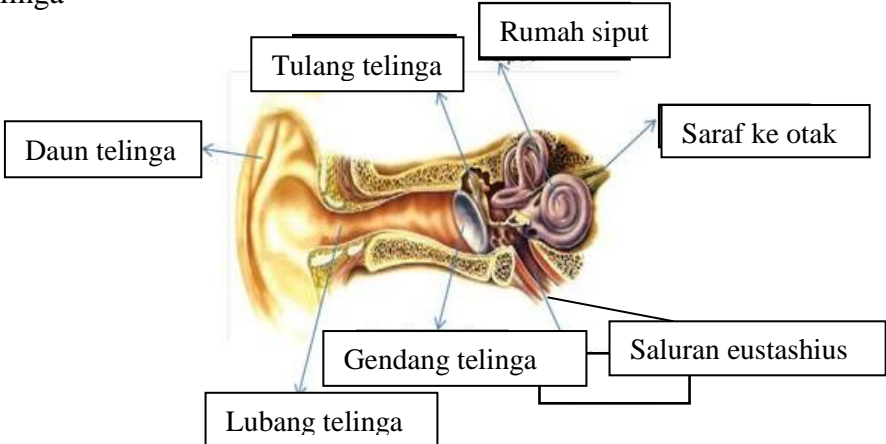
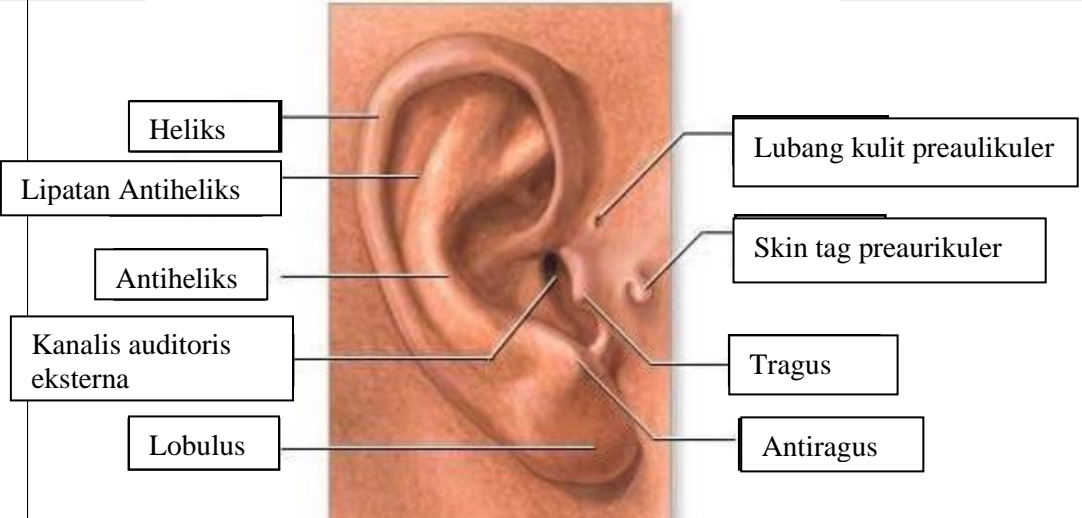
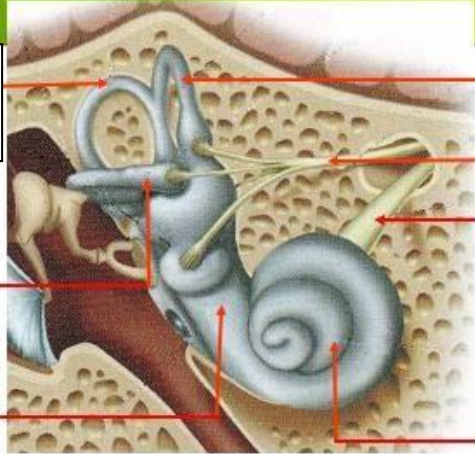
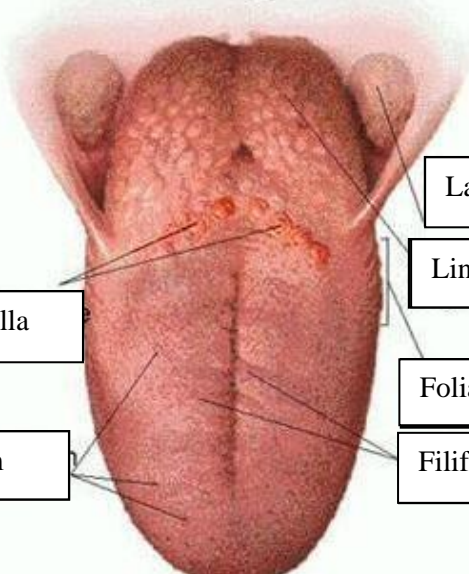


**WORKSHEETS (LEMBAR KERJA)**

<b>Mata Kuliah</b>	: <b>Anatomi</b>
<b>Materi</b>	: <b>Anatomi Panca Indra</b>
<b>NIM&gt;Nama Mahasiswa</b>	: <b>2110101052/ Anisah</b>

No	Keterangan	Pembahasan
1	<p>Mata</p> 	
	<p>Telinga</p> 	
		

No	Keterangan	Pembahasan
	<p data-bbox="268 315 475 432">Semicircular Canals</p> <p data-bbox="245 488 456 577">Vestibular complex</p> <p data-bbox="225 651 456 719">Tingkap bundar</p>	 <p data-bbox="1002 331 1331 409">Semicircular duct within anterior semicircular</p> <p data-bbox="991 443 1295 566">1. Malleus 2. Incus 3. Stapes</p> <p data-bbox="991 584 1211 640">Saraf kolesera</p> <p data-bbox="1002 663 1326 719">Konklev (rumah siput)</p>
	<p data-bbox="341 1032 671 1099">Circumvallate papilla</p> <p data-bbox="384 1178 660 1234">Papil fungiform</p>	 <p data-bbox="1007 898 1382 954">Langit-langit tenggorokan</p> <p data-bbox="1002 976 1241 1032">Lingual tonsil</p> <p data-bbox="991 1099 1254 1155">Foliate papillae</p> <p data-bbox="991 1178 1241 1234">Filiform papillae</p>