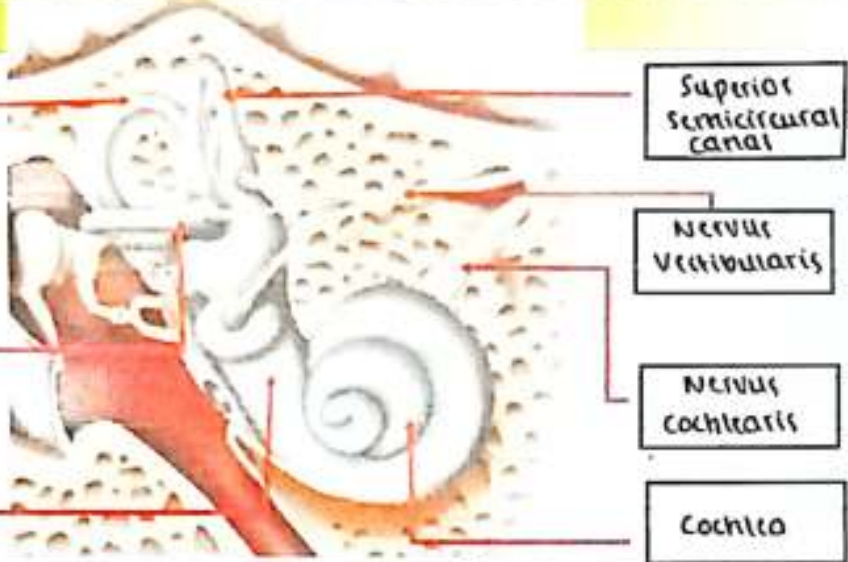
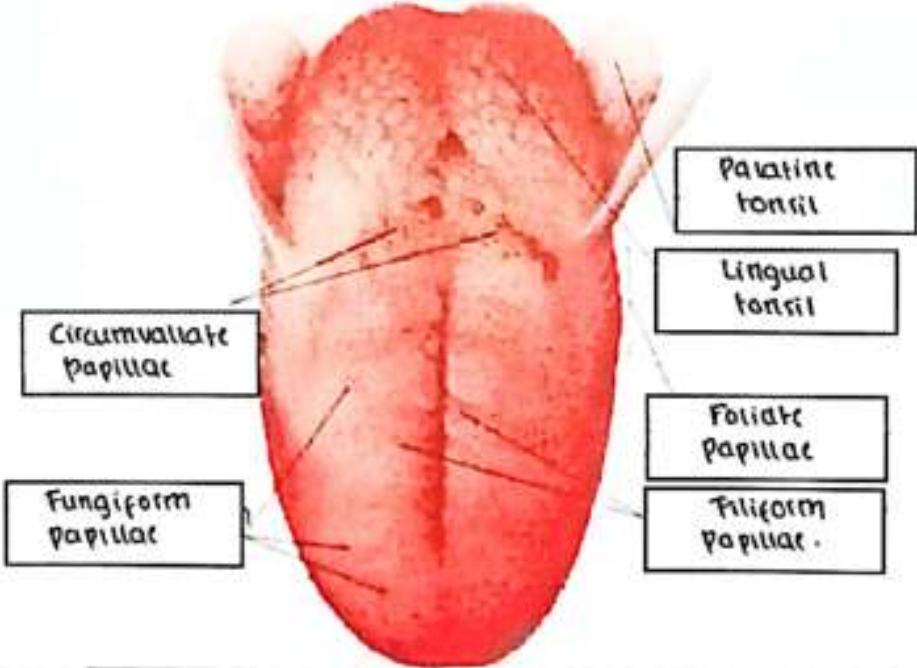


**WORKSHEETS (LEMBAR KERJA)**

Mata Kuliah	: Anatomi
Materi	: Anatomi Panca Indra
NIM>Nama Mahasiswa	: 2110101051 / Tjahya Pramudyaning. S.

No	Keterangan	Pembahasan
1	Mata	<p>Anatomical diagram of the eye showing internal structures. Labels on the left: Otot mata, Kornea, Iris, Pupl., Lens. Labels on the right: Retina, Saraf.</p>
2.	Telinga	<p>Anatomical diagram of the middle ear. Labels: Daun telinga, Tulang Pendengaran, Cochlea, Saraf ke otak, gendang telinga, Tube eustachius, saluran telinga.</p>
3.		<p>Anatomical diagram of the external ear. Labels on the left: Helix, Lipatan antiheliks, antiheliks, analis auditoris eksterno, Lobulus. Labels on the right: Lubang tuli preaurikuler, Kulit tag preaurikuler, Tragus, antitragus.</p>

No	Keterangan	Pembahasan
4.	<p>Posterior semicircular canal</p> <p>Lateral semicircular canal</p> <p>Vestibuli</p>	 <p>Superior semicircular canal</p> <p>Nervus Vestibularis</p> <p>Nervus Cochlearis</p> <p>Cochlea</p>
5.		 <p>Circumvallate papillae</p> <p>Fungiform papillae</p> <p>Palatine tonsil</p> <p>Lingual tonsil</p> <p>Foliate papillae</p> <p>Filiform papillae</p>