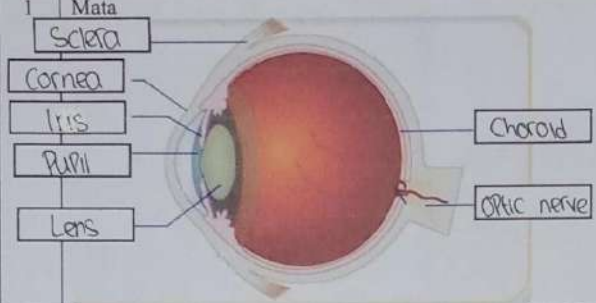
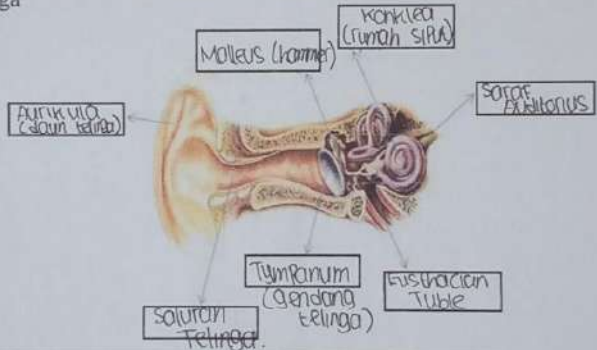
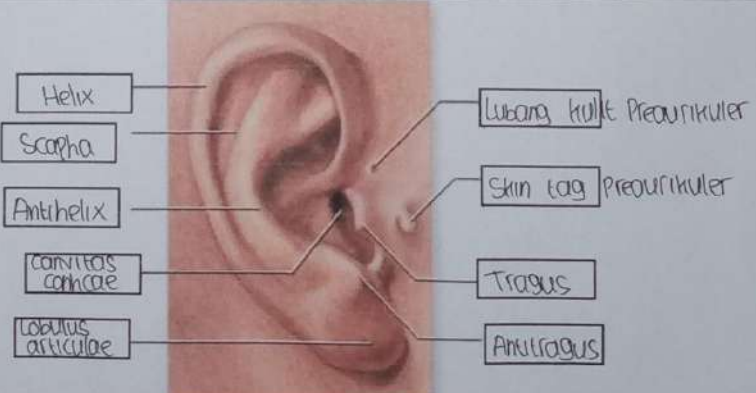


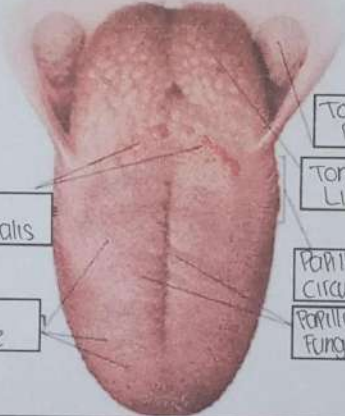
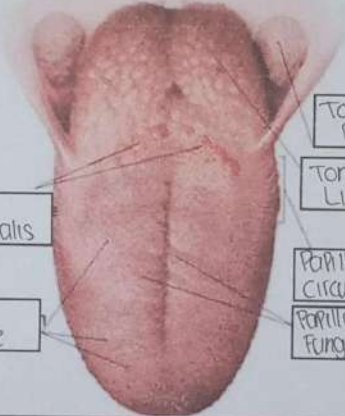


**WORKSHEETS (LEMBAR KERJA)**

Mata Kuliah	: Anatomi
Materi	: Anatomi Panca Indra
NIM>Nama Mahasiswa	: Nindra Arlindawati / 2110101097

No	Keterangan	Pembahasan
I	Mata	 <p>Labels for eye diagram: Sclera, Cornea, Iris, Pupil, Lens, Choroid, Optic nerve.</p>
	Telinga	 <p>Labels for middle ear diagram: Aurikula (daun telinga), Malleus (hammer), Incus (rumah siput), Semicircular canals, Tympanum (gendang telinga), Eustachian Tube, Salivary Gland.</p>
		 <p>Labels for external ear diagram: Helix, Scapha, Antihelix, Concha, Lobulus auriculæ, External acoustic meatus, Skin tag, Tragus, Auricle.</p>



No	Keterangan	Pembahasan
	 <p>Posterior semicircular canal</p> <p>Lateral semicircular canal</p> <p>Vestibular complex</p>	 <p>Posterior Semicircular canal</p> <p>Nervus Vestibularis</p> <p>Nervus Cochlearis</p> <p>Cochlea</p>
	 <p>Sulcus Terminalis</p> <p>Dorsum Linguae</p>	 <p>Tonsila Palatina</p> <p>Tonsila Lingualis</p> <p>Papilla Circumvalatae</p> <p>Papilla Fungiformes.</p>