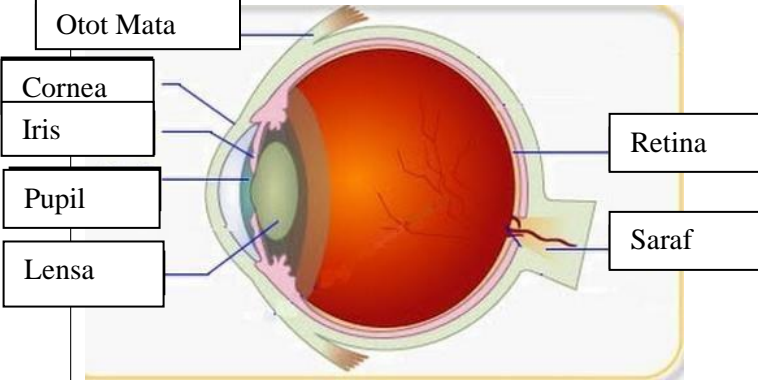
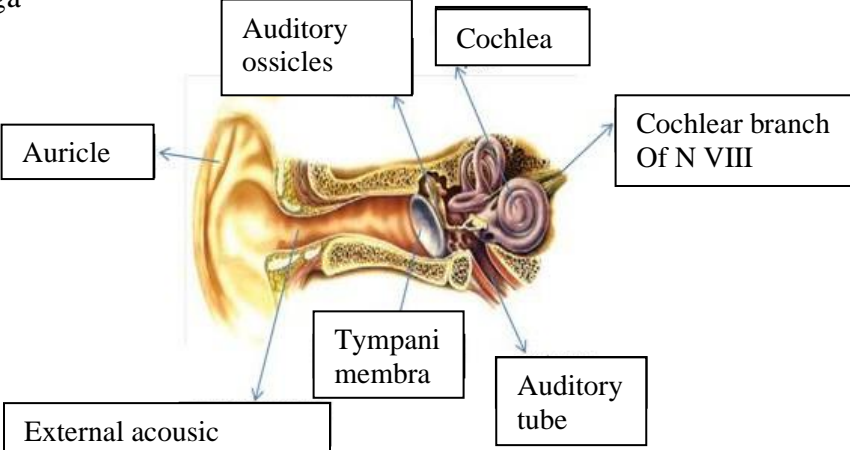

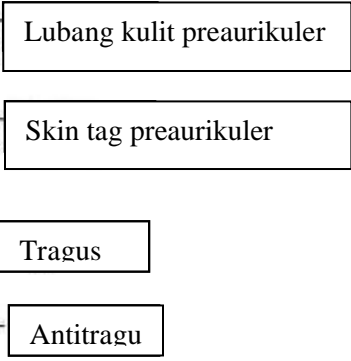
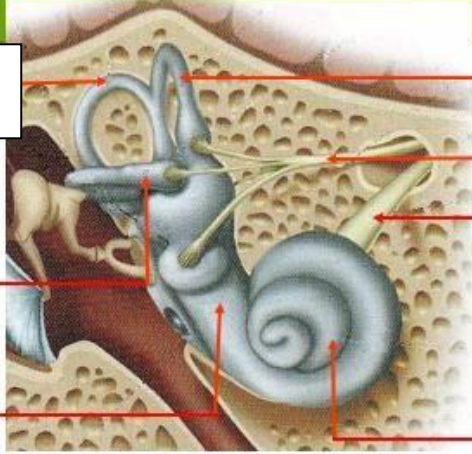
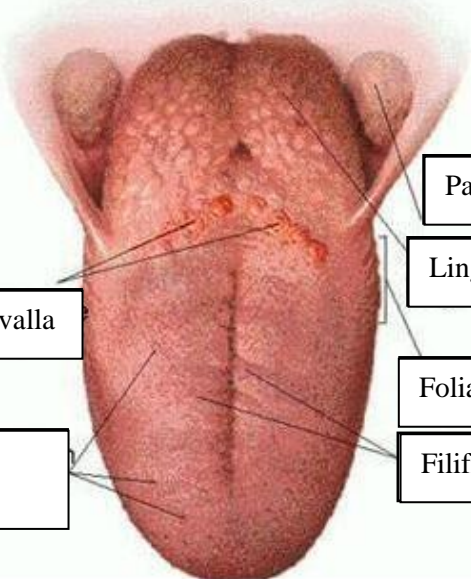


WORKSHEETS (LEMBAR KERJA)

Mata Kuliah	: Anatomi
Materi	: Anatomi Panca Indra
NIM>Nama Mahasiswa	: 2110101135/Ani khoeriyatul mardiyah

No	Keterangan	Pembahasan
1	<p>Mata</p> 	
	<p>Telinga</p> 	
		

No	Keterangan	Pembahasan
	 <p data-bbox="295 315 491 405">Semicircular Canals</p> <p data-bbox="295 483 453 573">Lateral</p> <p data-bbox="295 663 453 723">Vestibular complex</p>	<p data-bbox="991 327 1414 409">Semicircular canals within anterior semicircular canal</p> <p data-bbox="991 427 1267 551">1. Malleus 2. Incus 3. Stapes</p> <p data-bbox="991 568 1305 629">Saraf ruang siput</p> <p data-bbox="991 663 1305 723">Konkrec (rumah siput)</p>
		 <p data-bbox="475 1025 671 1099">Circumvalla</p> <p data-bbox="432 1167 660 1267">Fungiform papillae</p> <p data-bbox="991 898 1230 958">Palatine tonsil</p> <p data-bbox="991 981 1209 1041">Lingual tonsil</p> <p data-bbox="991 1099 1230 1160">Foliate papillae</p> <p data-bbox="991 1178 1251 1238">Filiform papillae</p>