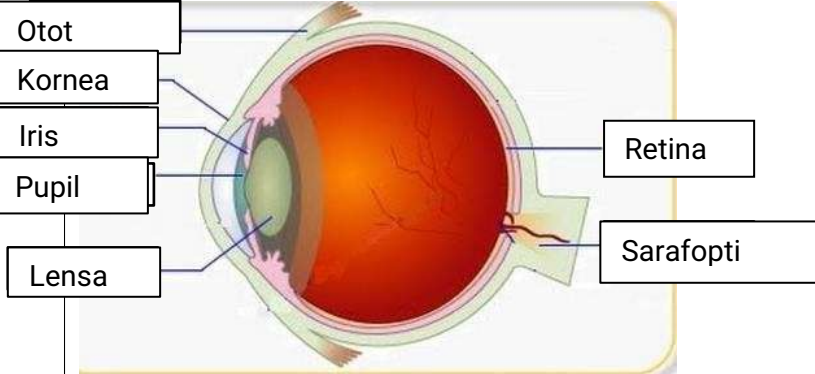
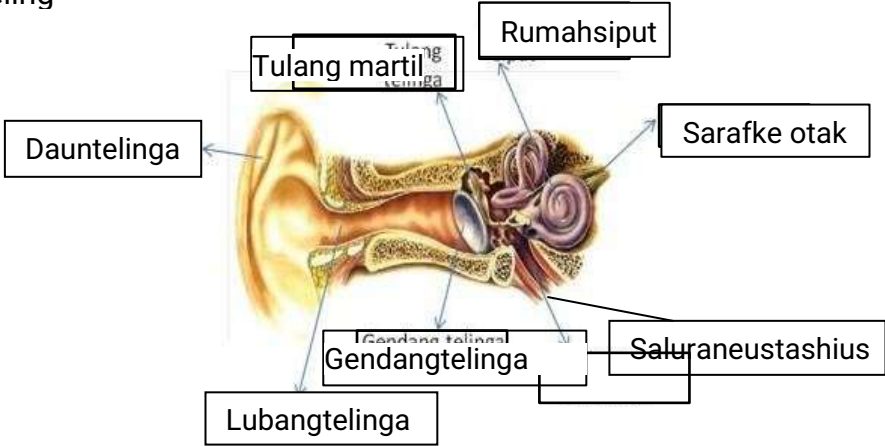
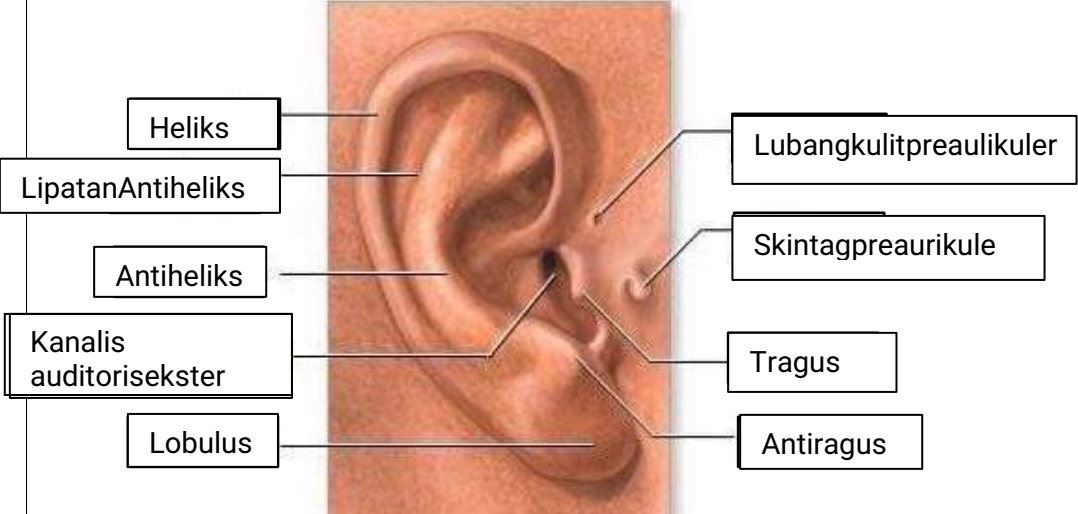


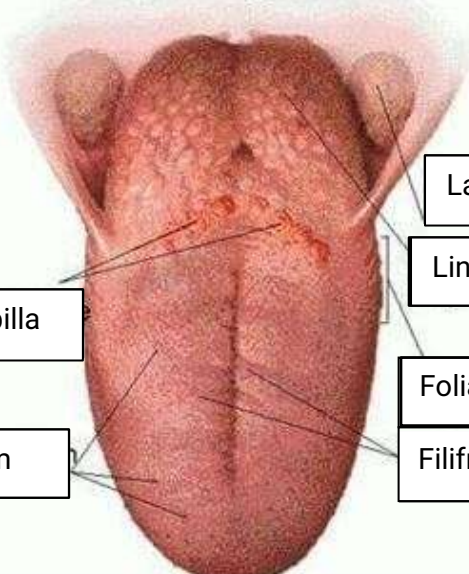
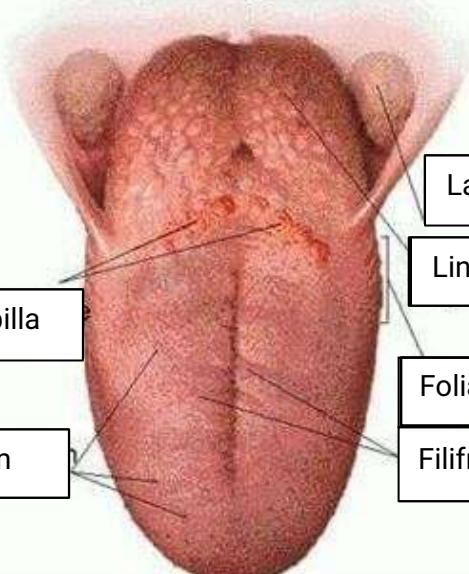


WORKSHEETS(LEMBARKERJA)

MataKuliah	: Anatomi
Materi	: Anatomi Panca Indra
NIM>NamaMahasiswa	: 2110101083/Riska Arinanda

No	Keterangan	Pembahasan
1	<p>Mat</p> 	
	<p>Teling</p> 	
		

N	Keteranga	Pembahasa
	 <p data-bbox="268 315 475 432">Semicircular canals</p> <p data-bbox="245 488 456 577">Vestibular complex</p> <p data-bbox="225 645 456 723">Middle ear</p>	 <p data-bbox="1002 331 1331 409">Semicircular canals within the internal ear</p> <p data-bbox="1002 443 1294 589">1. Malleus 2. Incus 3. Stapes</p> <p data-bbox="1002 667 1326 723">Cochlea (inner ear)</p>
	 <p data-bbox="344 1032 675 1099">Circumvallate papilla</p> <p data-bbox="384 1167 660 1234">Papillae fungiform</p>	 <p data-bbox="1007 898 1382 965">Oral cavity</p> <p data-bbox="1007 987 1241 1043">Lingual tonsil</p> <p data-bbox="991 1099 1246 1155">Foliate papillae</p> <p data-bbox="991 1167 1246 1234">Filiform papillae</p>