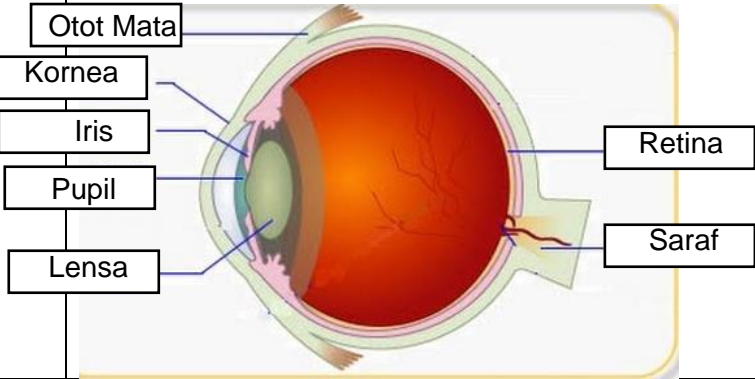
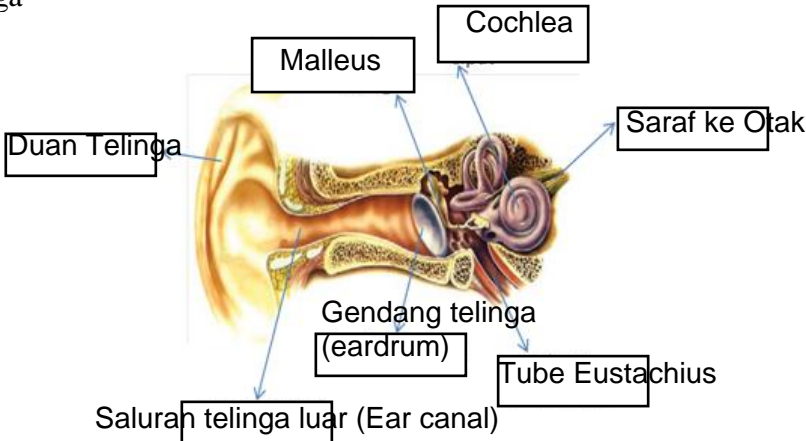
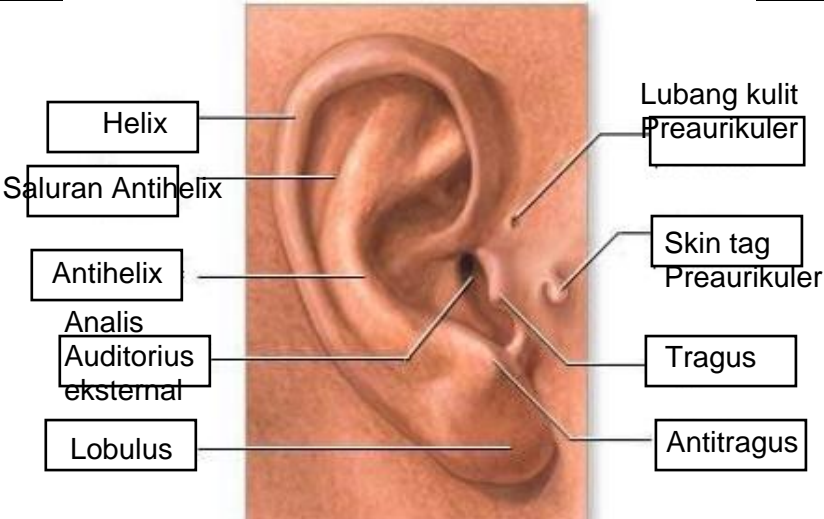
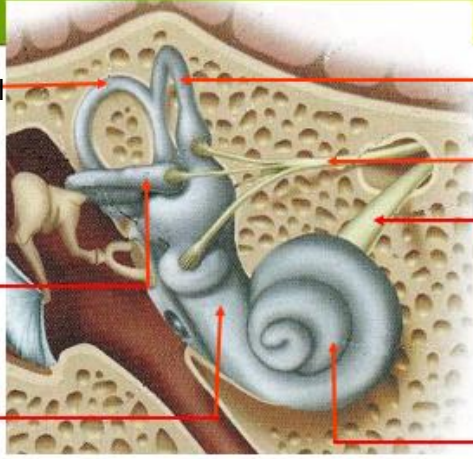
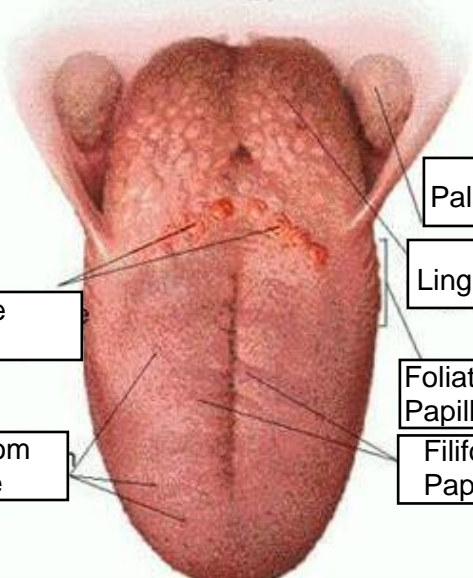


WORKSHEETS (LEMBAR KERJA)

Mata Kuliah	: Anatomi
Materi	: Anatomi Panca Indra
NIM>Nama Mahasiswa	: 2110101092/Dinanda Dwi Setyorini

No	Keterangan	Pembahasan
1	<p>Mata</p> 	
	<p>Telinga</p> 	
		

No	Keterangan	Pembahasan
	<p>Posterior Semucircular canal</p> <p>Lateral Semucircular canal</p> <p>Vestibuli</p>	 <p>Superior Semucircular canal</p> <p>Nervus Versibularis</p> <p>Nervus Cochlearis</p> <p>Cochlea</p>
	<p>Papillae Vallate</p> <p>Fungiform Papillae</p>	 <p>Palatine tonsil</p> <p>Lingual Tonsil</p> <p>Foliate Papillae</p> <p>Filiform Papillae</p>