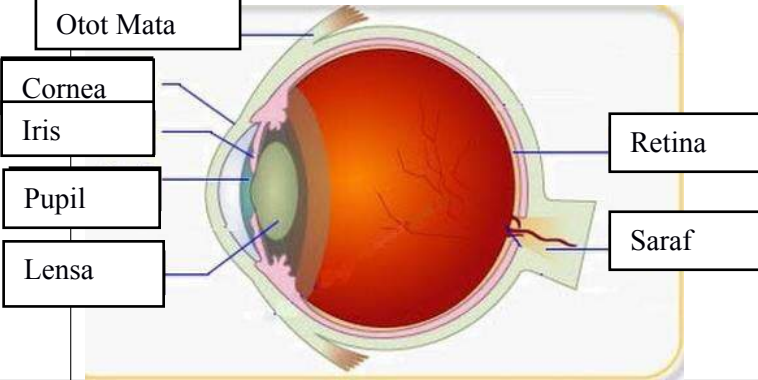
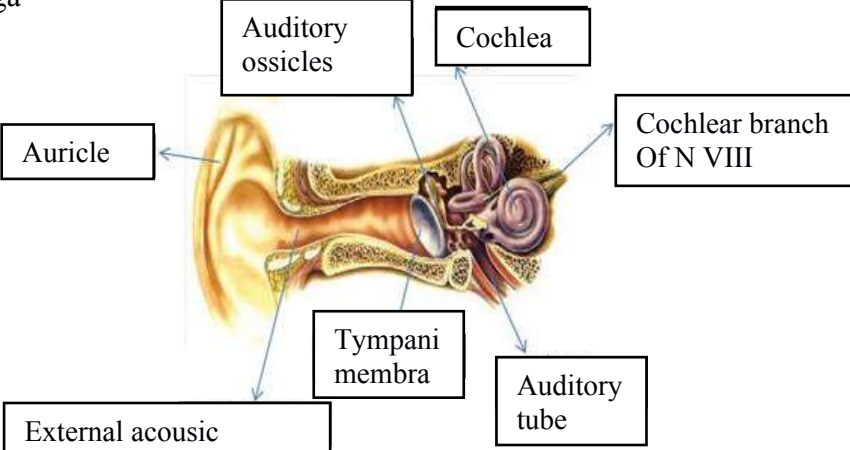

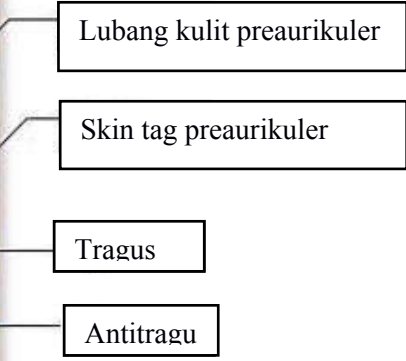
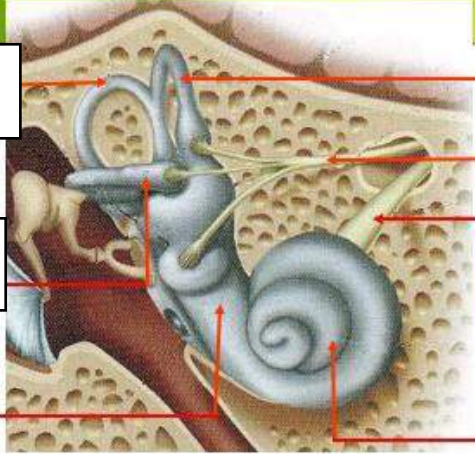
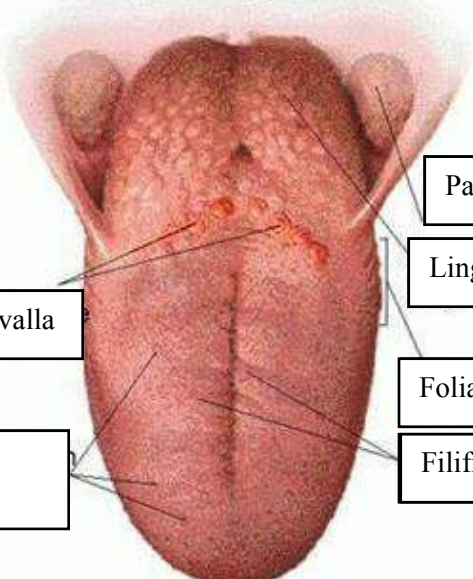


WORKSHEETS (LEMBAR KERJA)

Mata Kuliah	: Anatomi
Materi	: Anatomi Panca Indra
NIM>Nama Mahasiswa	: 2110101135/Ani khoeriyatul mardiyah

No	Keterangan	Pembahasan
1	<p>Mata</p> 	
	<p>Telinga</p> 	
		

No	Keterangan	Pembahasan
	 <p data-bbox="304 322 491 405">Semicircular Canals</p> <p data-bbox="304 495 491 577">Vestibular complex</p> <p data-bbox="304 667 453 730"></p>	<p data-bbox="1002 331 1414 405">Semicircular canals within anterior semicircular canal</p> <p data-bbox="1002 434 1267 555"> 1. Malleus 2. Incus 3. Stapes </p> <p data-bbox="1002 568 1232 636"></p> <p data-bbox="1002 667 1305 730">Konkrec (rumah siput)</p>
		 <p data-bbox="1002 898 1232 958">Palatine tonsil</p> <p data-bbox="1002 987 1214 1048">Lingual tonsil</p> <p data-bbox="475 1032 671 1093">Circumvallata</p> <p data-bbox="432 1167 660 1272">Fungiform papillae</p> <p data-bbox="1002 1099 1232 1160">Foliate papillae</p> <p data-bbox="1002 1167 1254 1249">Filiform papillae</p>