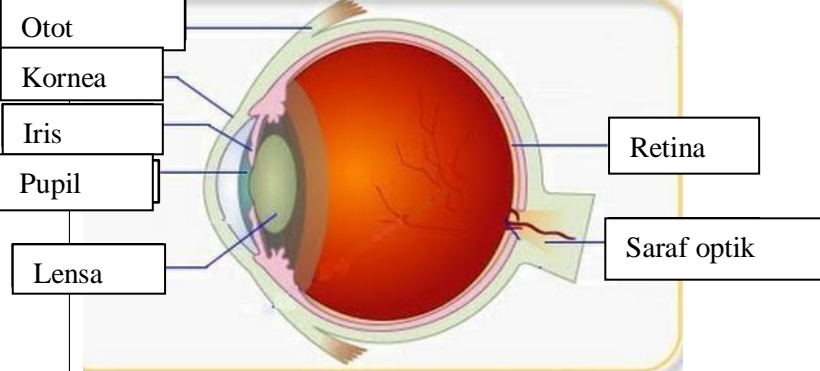

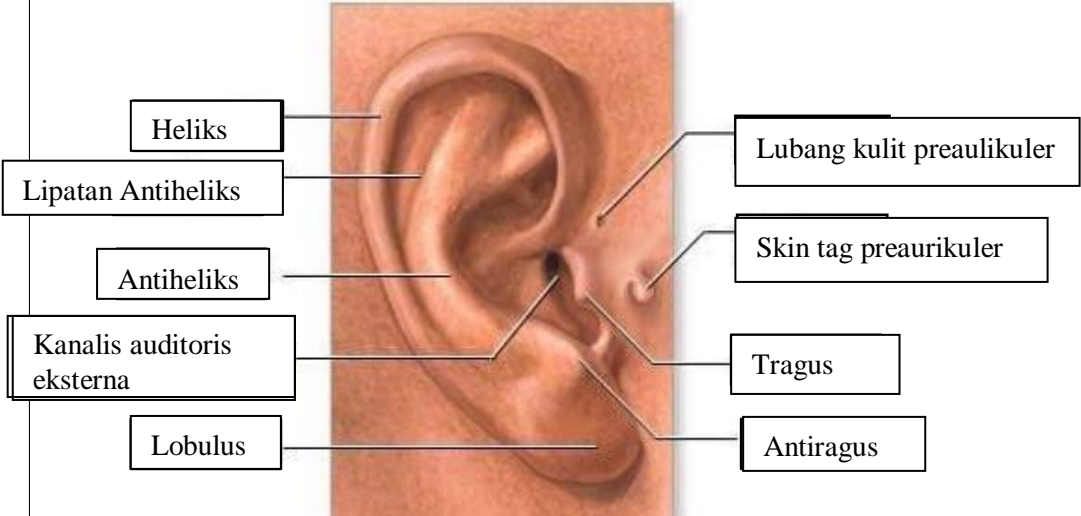

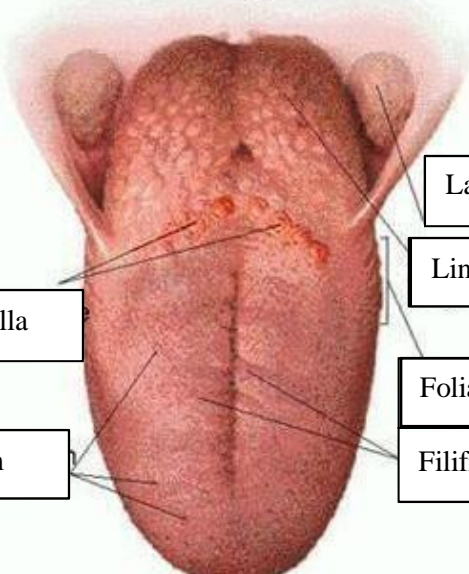


WORKSHEETS (LEMBAR KERJA)

Mata Kuliah	: Anatomi
Materi	: Anatomi Panca Indra
NIM>Nama Mahasiswa	: 2110101081/ Deby Amnasari

No	Keterangan	Pembahasan
1	Mata	 <p>Diagram of the human eye showing internal structures. Labels on the left: Otot, Kornea, Iris, Pupil, Lensa. Labels on the right: Retina, Saraf optik.</p>
	Telinga	 <p>Diagram of the human ear showing internal structures. Labels: Daun telinga, Tulang telinga, Rumah siput, Saraf ke otak, Gendang telinga, Saluran eustachius, Lubang telinga.</p>
		 <p>Photograph of a human ear with external structure labels. Labels on the left: Heliks, Lipatan Antiheliks, Antiheliks, Kanalis auditoris eksterna, Lobulus. Labels on the right: Lubang kulit preaulikuler, Skin tag preaurikuler, Tragus, Antiragus.</p>

No	Keterangan	Pembahasan
	 <p data-bbox="268 322 475 432">Semicircular Canals</p> <p data-bbox="248 488 456 577">Vestibular complex</p> <p data-bbox="225 651 456 719">Tingkap bundar</p>	<p data-bbox="1002 327 1329 416">Semicircular duct within anterior semicircular</p> <p data-bbox="991 443 1294 573">1. Malleus 2. Incus 3. Stapes</p> <p data-bbox="1002 584 1209 640">Saraf kolesera</p> <p data-bbox="1002 663 1326 719">Koklea (rumah siput)</p>
	 <p data-bbox="344 1032 671 1099">Circumvallate papilla</p> <p data-bbox="384 1178 655 1234">Papil fungiform</p>	<p data-bbox="1007 898 1382 965">Langit-langit tenggorokan</p> <p data-bbox="1002 976 1241 1043">Lingual tonsil</p> <p data-bbox="991 1099 1190 1155">Foliate papillae</p> <p data-bbox="991 1178 1246 1234">Filiform papillae</p>