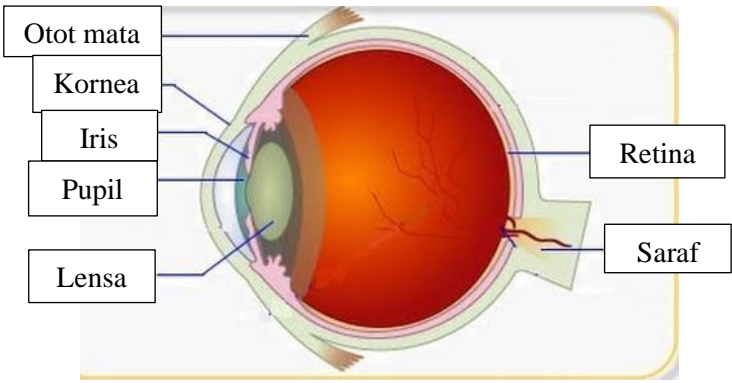
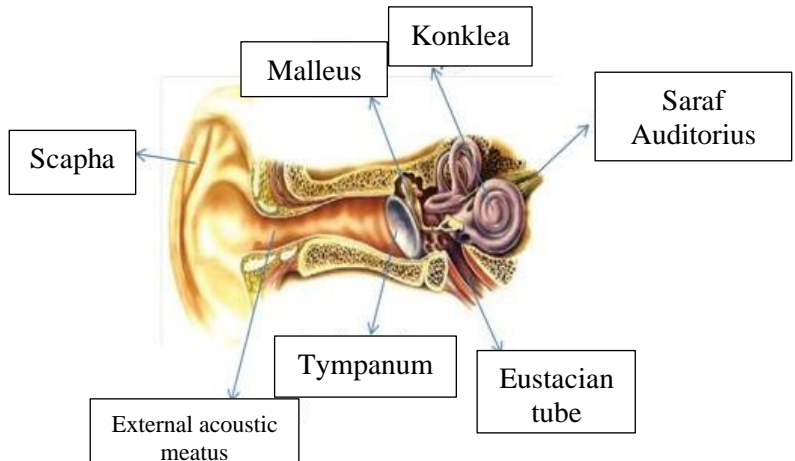
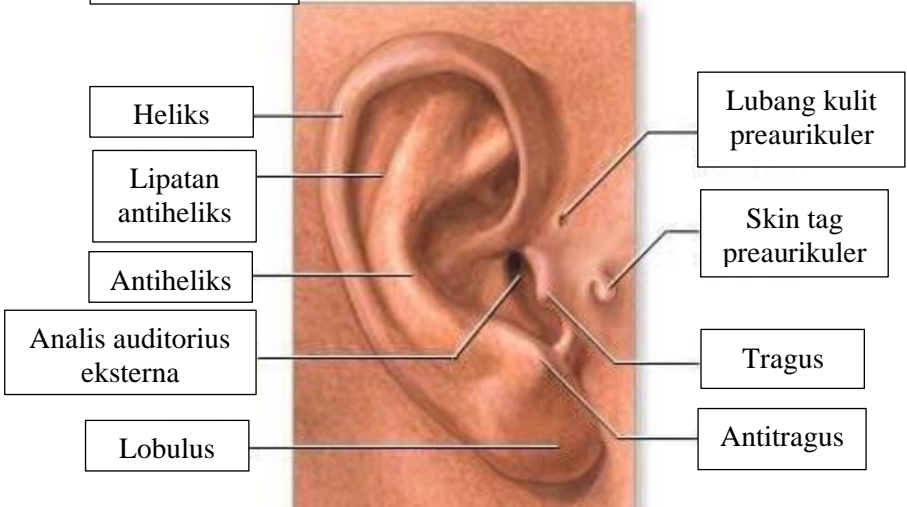

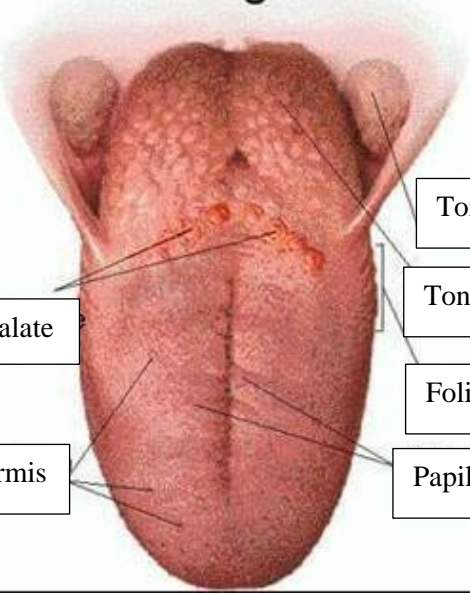


WORKSHEETS (LEMBAR KERJA)

Mata Kuliah	: Anatomi
Materi	: Anatomi Panca Indra
NIM>Nama Mahasiswa	: 2110101088/Shalihati Al Izzati

No	Keterangan	Pembahasan
1	Mata	 <p>Anatomical diagram of the human eye showing internal structures. Labels on the left: Otot mata, Kornea, Iris, Pupil, Lensa. Labels on the right: Retina, Saraf.</p>
	Telinga	 <p>Anatomical diagram of the middle ear showing ossicles and other structures. Labels: Scapha, Malleus, Konklea, Saraf Auditorius, Tympanum, Eustacian tube, External acoustic meatus.</p>
		 <p>Anatomical diagram of the external ear showing cartilaginous parts. Labels on the left: Heliks, Lipatan antiheliks, Antiheliks, Analis auditorius eksterna, Lobulus. Labels on the right: Lubang kulit preaurikuler, Skin tag preaurikuler, Tragus, Antitragus.</p>

No	Keterangan	Pembahasan
	<p>Posterior Semicircular canal</p> <p>Lateral Semicircular canal</p> <p>Vestibuli</p>	 <p>Superior Semicircular canal</p> <p>Nervus Vestibularis</p> <p>Nervus Cochlearis</p> <p>Cochlea</p>
	<p>Papilla Circumvalate</p> <p>Papila Fungiformis</p>	 <p>Tonsila Palatina</p> <p>Tonsila Lingualis</p> <p>Foliate Papillae</p> <p>Papila Filiformis</p>