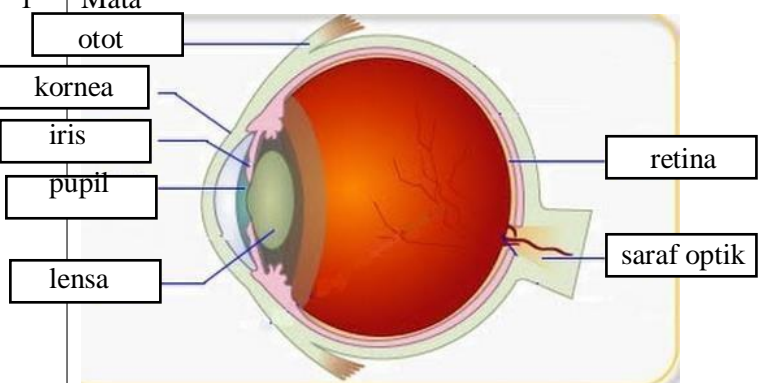
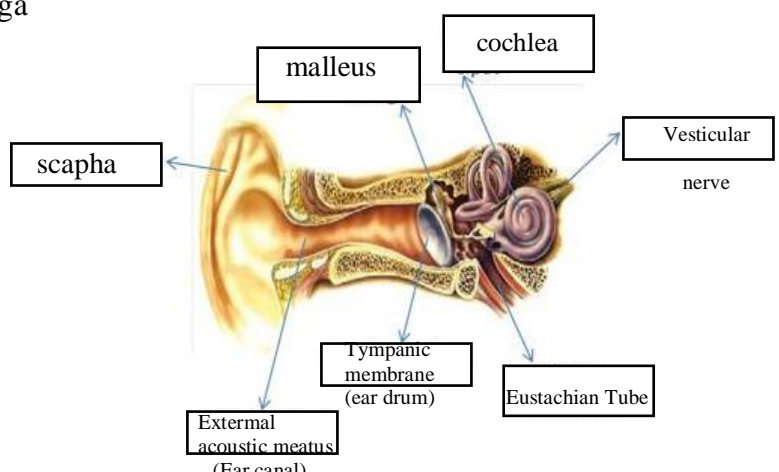
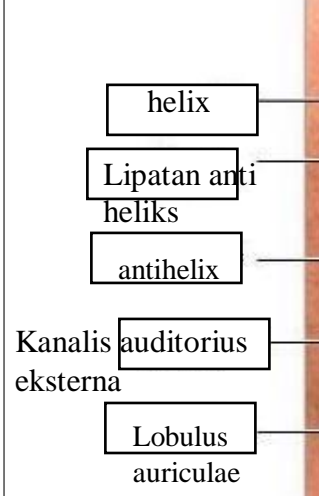

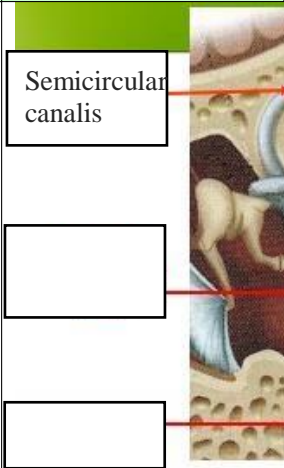
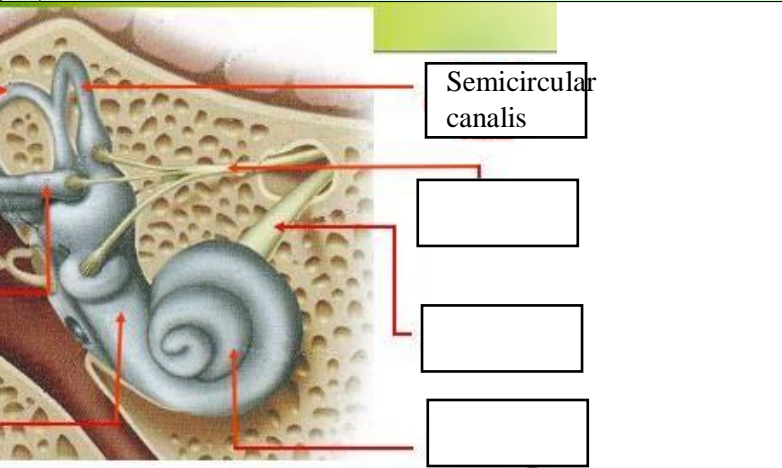
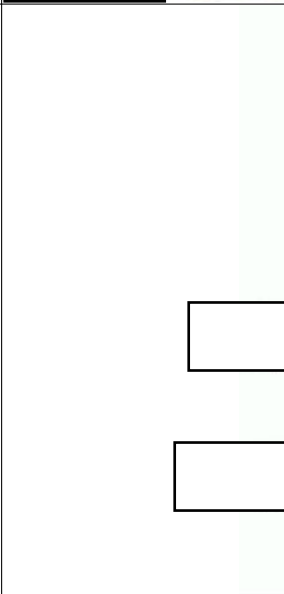
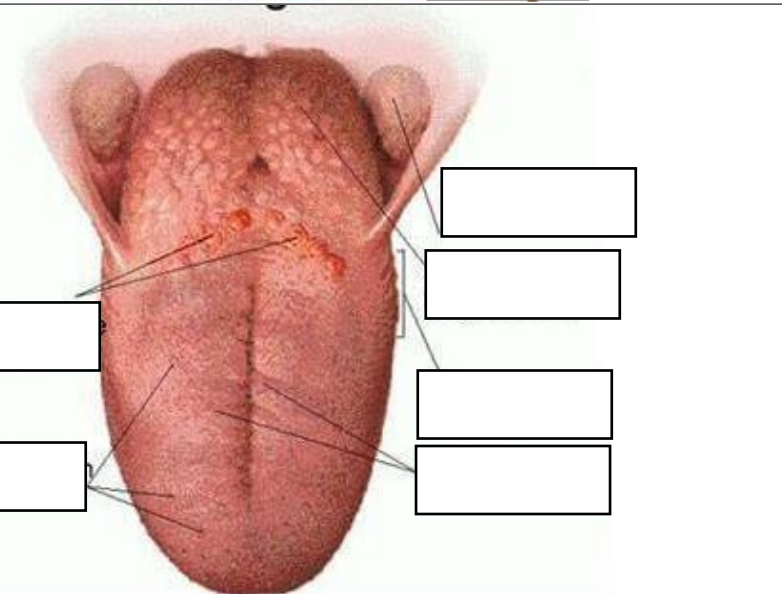


WORKSHEETS (LEMBAR KERJA)

Mata Kuliah	: Anatomi
Materi	: Anatomi Panca Indra
NIM>Nama Mahasiswa	: 2110101085/ Hanani Uswatun Hasanah

No	Keterangan	Pembahasan
1	<p>Mata</p> 	
	<p>Telinga</p> 	
		

No	Keterangan	Pembahasan
	 <p>Semicircular canalis</p> <p>[Empty box]</p> <p>[Empty box]</p>	 <p>Semicircular canalis</p> <p>[Empty box]</p> <p>[Empty box]</p> <p>[Empty box]</p>
	 <p>[Empty box]</p> <p>[Empty box]</p> <p>[Empty box]</p>	 <p>[Empty box]</p> <p>[Empty box]</p> <p>[Empty box]</p> <p>[Empty box]</p>

Telinga bagian dalam dr atas ke bawah :

1. Semicircular analis
2. semicircular canalis
3. vestibulus complex
4. semicircular canalis
5. vestibular nerve atau saraf
6. cochlea nerve
7. cochlea

Bagian lidah dr atas ke bawah :

1. Circumvallate Papillae
2. Fungiform Papillae
3. Palatine Tonsil
4. Lingual Tonsil
5. Foliate Papillae
6. Filiform Papillae