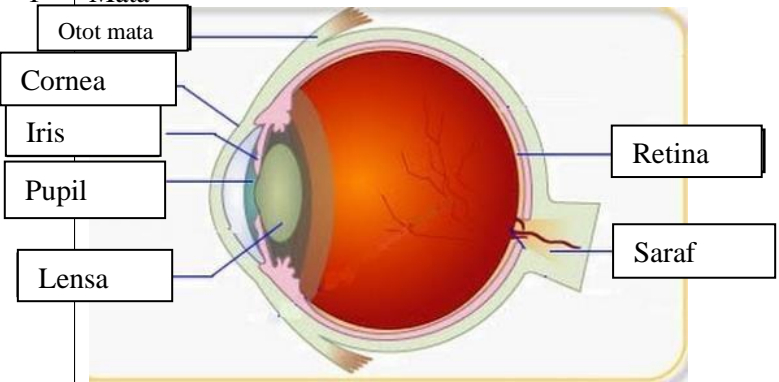
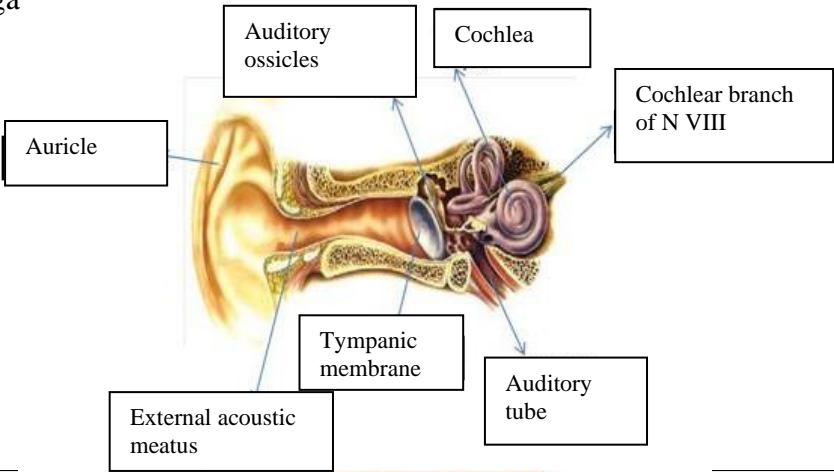
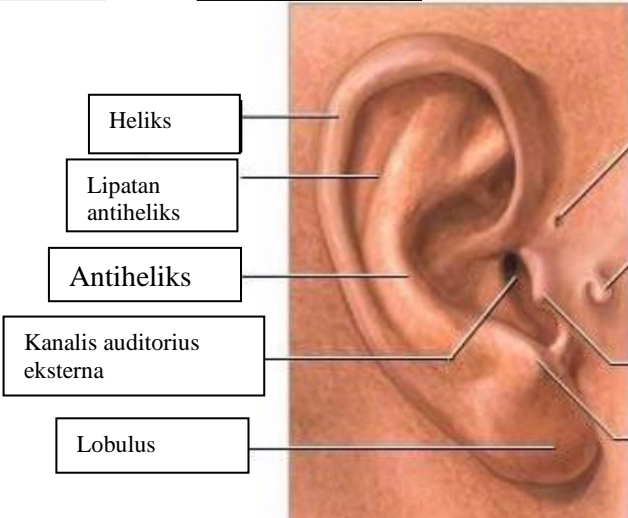
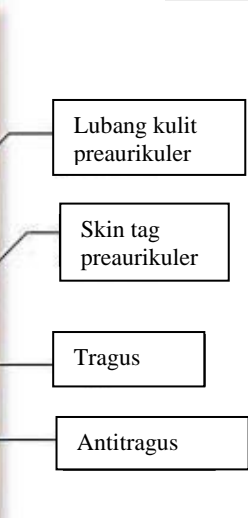


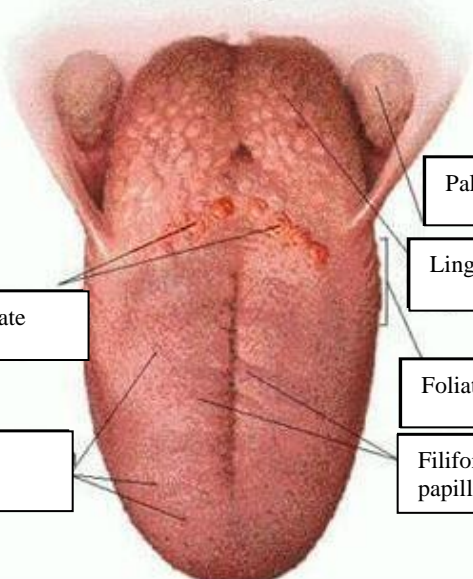
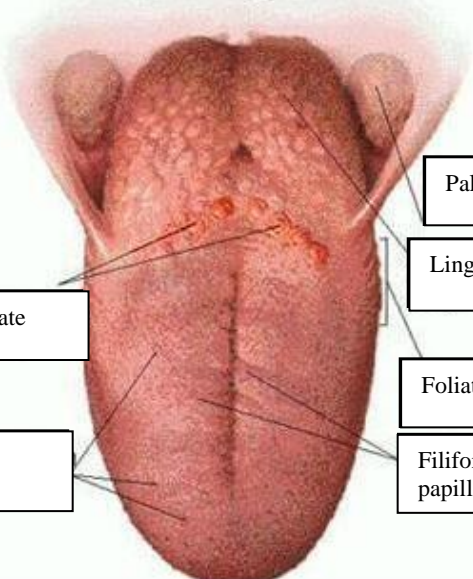


WORKSHEETS (LEMBAR KERJA)

Mata Kuliah	: Anatomi
Materi	: Anatomi Panca Indra
NIM>Nama Mahasiswa	: 2110101089/ Evi Nofiandari

No	Keterangan	Pembahasan
1	<p>Mata</p> 	
	<p>Telinga</p> 	
		

No	Keterangan	Pembahasan
	 <p data-bbox="240 315 480 409">Posterior semicircular canal</p> <p data-bbox="240 483 480 577">Lateral semicircular canal</p> <p data-bbox="296 651 480 730">Vestibular complex</p>	 <p data-bbox="991 315 1214 409">Superior semicircular canal</p> <p data-bbox="991 443 1241 521">Vestibular branch N of VIII</p> <p data-bbox="991 555 1214 633">Cochlear branch of N VIII</p> <p data-bbox="991 651 1177 730">Cochlea</p>
	 <p data-bbox="464 1025 679 1104">circumvallate</p> <p data-bbox="464 1167 663 1245">Fungiform papillae</p>	 <p data-bbox="991 898 1214 976">Palatine tonsil</p> <p data-bbox="991 987 1193 1066">Lingual tonsil</p> <p data-bbox="991 1099 1185 1178">Foliate papillae</p> <p data-bbox="991 1189 1193 1267">Filiform papillae</p>