

WORKSHEETS (LEMBAR KERJA)

Mata Kuliah	: Anatomi
Materi	: Anatomi Panca Indra
NIM>Nama Mahasiswa	: 2110101093 / Nurul Fajila

No	Keterangan	Pembahasan
----	------------	------------



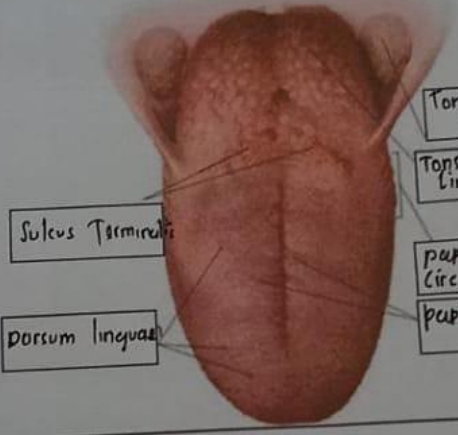
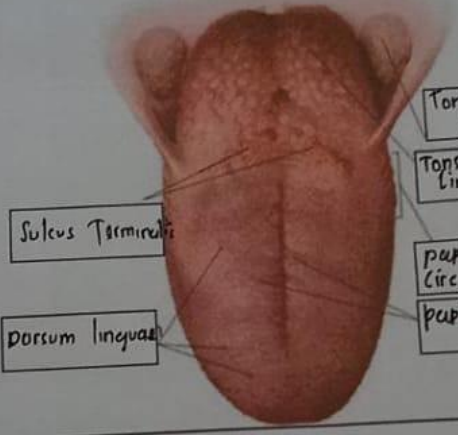
1 Mata

Anterior pole
Iris
Pupil
Lens
Retina
Optic nerve

Telinga

Daun telinga
Tulang telinga
Rumah siput
saraf ke otak
Gendang telinga
Saluran eustachius
lubang telinga

Helix
lipatan antiheliks
antiheliks
kanalis auditorius eksterna
lobulus auriculae
lubang kulit preaurikuler
skin tag
preaurikuler
Tragus
antitragus

No	Keterangan	Pembahasan
	 <p data-bbox="402 399 527 472">Posterior Semicircular Canal</p> <p data-bbox="402 514 527 588">Lateral Semi-Circular Canal</p> <p data-bbox="402 651 527 693">Vestibuli</p>	 <p data-bbox="925 367 1047 441">Superior Semicircular Canal</p> <p data-bbox="925 451 1047 514">Nervus Vestibularis</p> <p data-bbox="925 535 1047 598">Nervus Cochlearis</p> <p data-bbox="925 609 1047 661">Cochlea</p>
	 <p data-bbox="552 903 714 955">Sulcus Terminalis</p> <p data-bbox="544 1008 706 1060">Dorsum Linguae</p>	 <p data-bbox="958 777 1112 840">Tonsilla Palatina</p> <p data-bbox="958 850 1112 913">Tonsilla Lingualis</p> <p data-bbox="958 934 1112 997">Papilla Circumvalata</p> <p data-bbox="958 997 1161 1060">Papilla fungiformis</p>