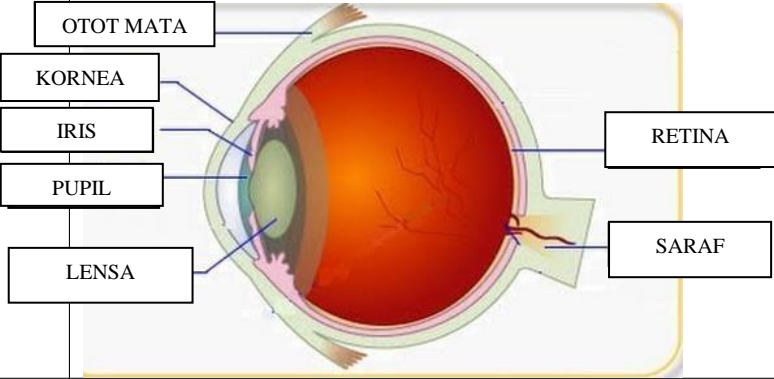
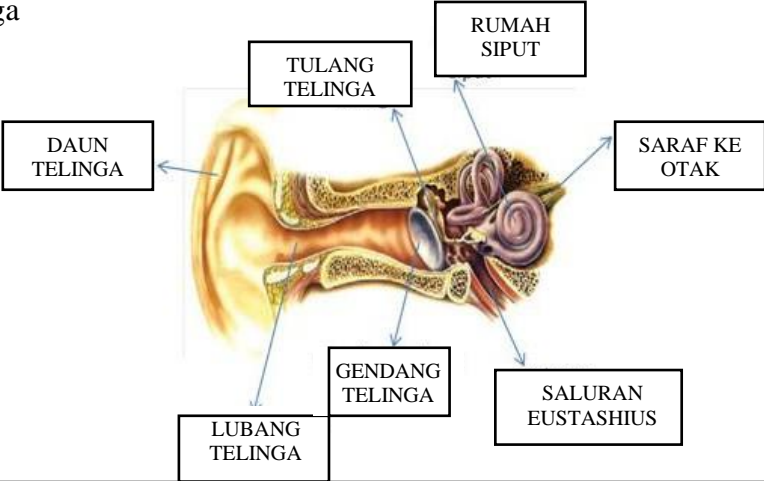
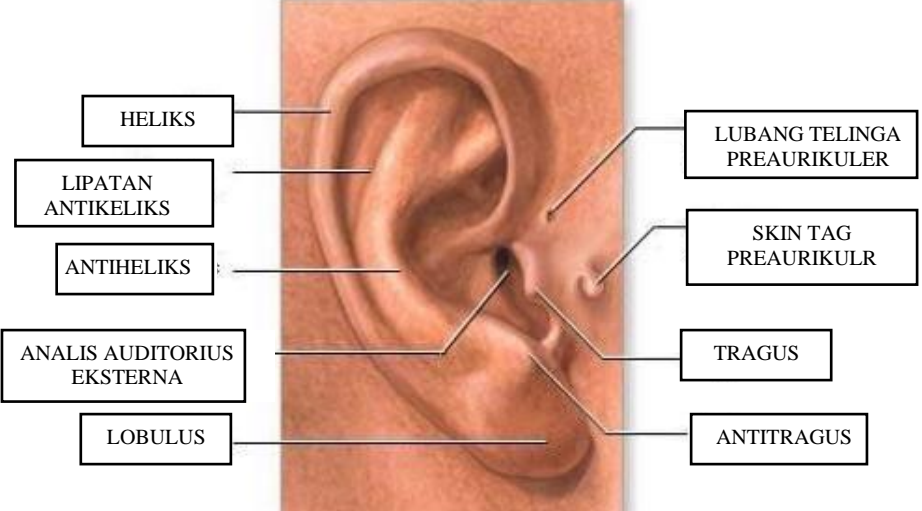
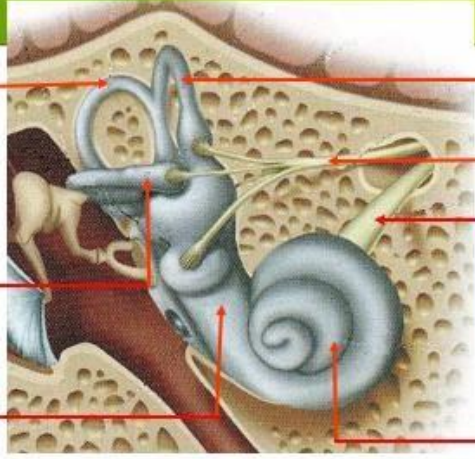
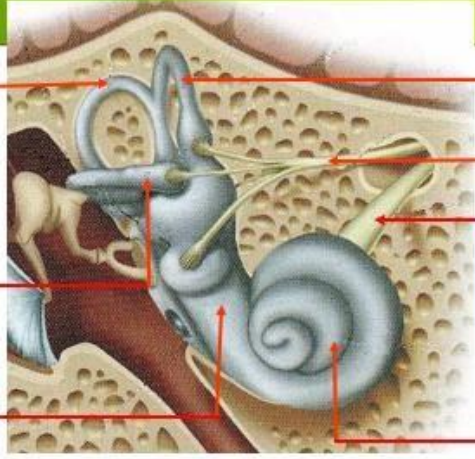
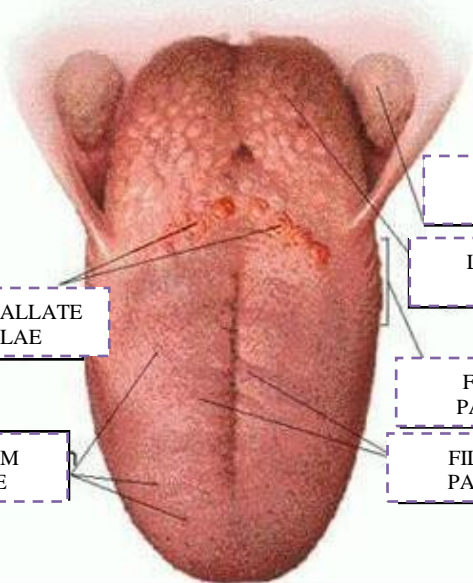


**WORKSHEETS (LEMBAR KERJA)**

<b>Mata Kuliah</b>	: <b>Anatomi</b>
<b>Materi</b>	: <b>Anatomi Panca Indra</b>
<b>NIM&gt;Nama Mahasiswa</b>	: <b>2110101082/SITI MAESARAH</b>

No	Keterangan	Pembahasan
1	<p>Mata</p> 	
	<p>Telinga</p> 	
		

No	Keterangan	Pembahasan
	 <p data-bbox="272 331 456 409">Semoisoulas candals</p> <p data-bbox="272 488 456 566">Tingkap bundar</p> <p data-bbox="272 667 456 723">VESTIBULAR COMPLEX</p>	 <p data-bbox="999 331 1182 409">Semicircules cluct Within anterior semicor</p> <p data-bbox="983 443 1238 521">VESTIBULAR BRANCH OF N VIII</p> <p data-bbox="999 566 1262 645">COCHLEAR BRANCH OF N VIII</p> <p data-bbox="999 667 1182 723">COCHLEA</p>
		 <p data-bbox="464 1025 695 1104">CIRCUMVALLATE PAPILLAE</p> <p data-bbox="432 1171 663 1249">FUNGIFORM PAPILLAE</p> <p data-bbox="1007 902 1238 981">PALATINE TONSIL</p> <p data-bbox="1007 992 1214 1070">LINGUAL TONSIL</p> <p data-bbox="991 1104 1214 1182">FOLIATE PAPILLAE</p> <p data-bbox="975 1171 1206 1249">FILIFORM PAPILLAE</p>