

WORKSHEETS (LEMBAR KERJA)

Mata Kuliah	: Anatomi
Materi	: Anatomi Panca Indra
NIM>Nama Mahasiswa	: 2110101123 / Helisa Layyinatusschyfa

No	Keterangan	Pembahasan
1	<p>Mata</p> <p>Labels: Superior, Cornea, Iris, Pupil, Lens, Rectus muscle, Retina, Optic nerve</p>	
	<p>Telinga</p> <p>Labels: Helix / daun telinga, Ossicula auditus, Cochlea, Auditory nerve / Nerves to the central Auditory system and brain: - Vestibular nerve, - Facial nerve, - Cochlear nerve, Tympanic membrane, Eustachian tube / Saluran Eustachius, Car canal external, Auditory canal external</p>	
	<p>Labels: Heliks, Lipatan antiheliks, Antiheliks, Kanalis auditorius eksternal, Lobulus auricularae, Lubang kulit Preaurikular, Skin tag Preaurikular, Tragus, Antitragus</p>	

No	Keterangan	Pembahasan
----	------------	------------




Diagram of the inner ear with the following labels:

- Posterior Semicircular Canal
- Lateral Semicircular Canal
- Vestibule
- Superior Semicircular Canal
- Vestibular nerve
- cochlear nerve
- Cochlea

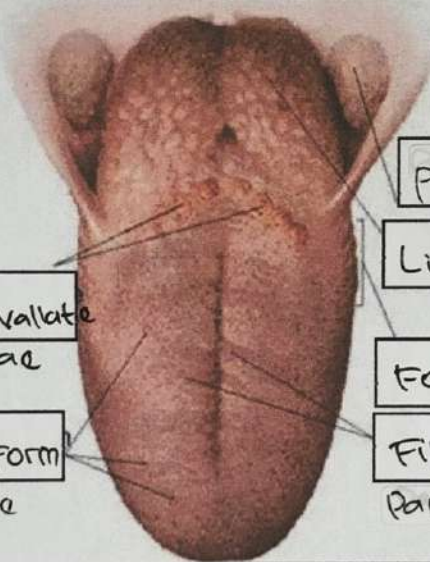


Diagram of the tongue with the following labels:

- Circumvallate Papillae
- FungiForm Papillae
- palatine tonsil
- Lingual tonsil
- Foliate Papillae
- FiliForm Papillae