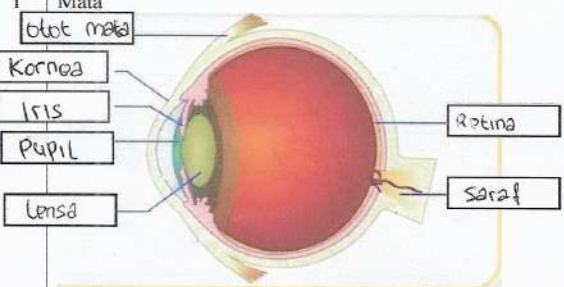

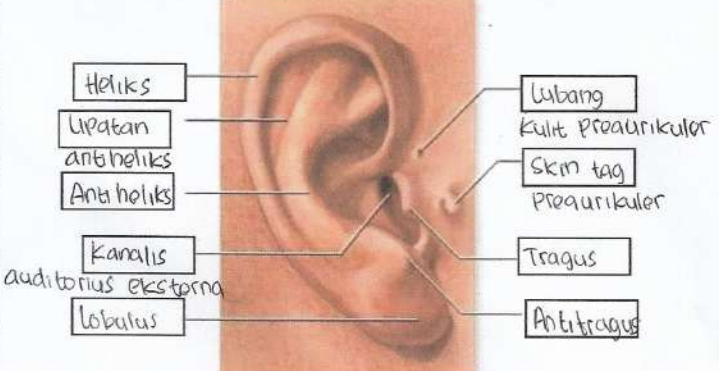

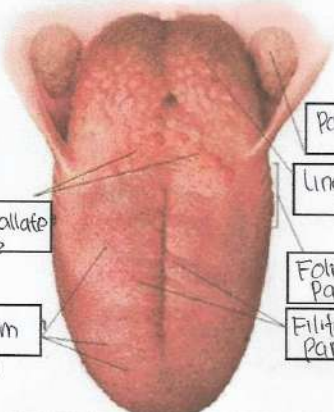


WORKSHEETS (LEMBAR KERJA)

| | |
|--------------------|-----------------------------------|
| Mata Kuliah | : Anatomi |
| Materi | : Anatomi Panca Indra |
| NIM>Nama Mahasiswa | : 2110101128 / ABRIEL EKA ZULFANI |

| No | Keterangan | Pembahasan |
|----|------------|--|
| 1 | Mata |  <p>Diagram of the human eye showing internal structures. Labels include: Kornea (Cornea), Iris, Pupil, Lensa (Lens), Retina, and Saraf (Nerve).</p> |
| | Telinga |  <p>Diagram of the human ear showing internal structures. Labels include: Daun Telinga (Pinna), Tulang Telinga (Ear Bones), Rumah Telinga (Cochlea), Siput (Snail), Saraf ke otak (Nerve to brain), Bendang Telinga (Eardrum), Saluran Eustachius (Eustachian Tube), and Lubang Telinga (Ear Hole).</p> |
| | |  <p>Diagram of the external ear showing external structures. Labels include: Heliks (Helix), Lipatan antiheliks (Antihelix fold), Anti heliks (Antihelix), Kanalis auditorius eksterna (External auditory canal), Lobulus (Lobule), Lubang Kulit Preaurikuler (Preauricular skin hole), Skm tag Preaurikuler (Preauricular skin tag), Tragus, and Anti tragus.</p> |

| No | Keterangan | Pembahasan |
|----|---|--|
| | <p>posterior</p> <p>lateral</p> <p>vestibular complex</p> |  <p>Saluran setengah lingkaran</p> <p>Saraf vestibular</p> <p>Saraf ruang siput</p> <p>Koklea</p> |
| | |  <p>Palatine Tonsil</p> <p>Lingual Tonsil</p> <p>Circumvallate papillae</p> <p>Foliate Papillae</p> <p>Fungiform Papillae</p> <p>Filiform Papillae</p> |