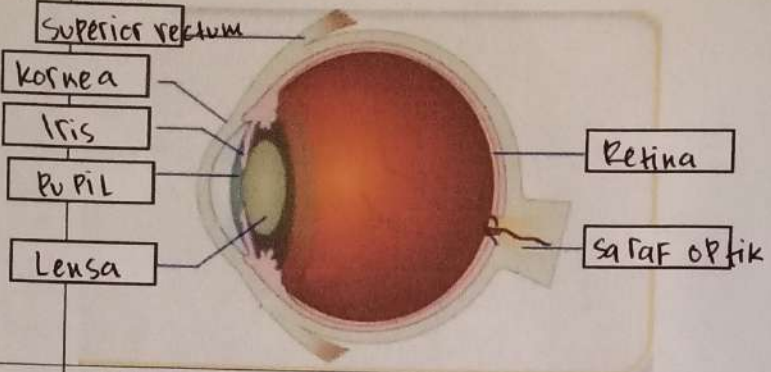

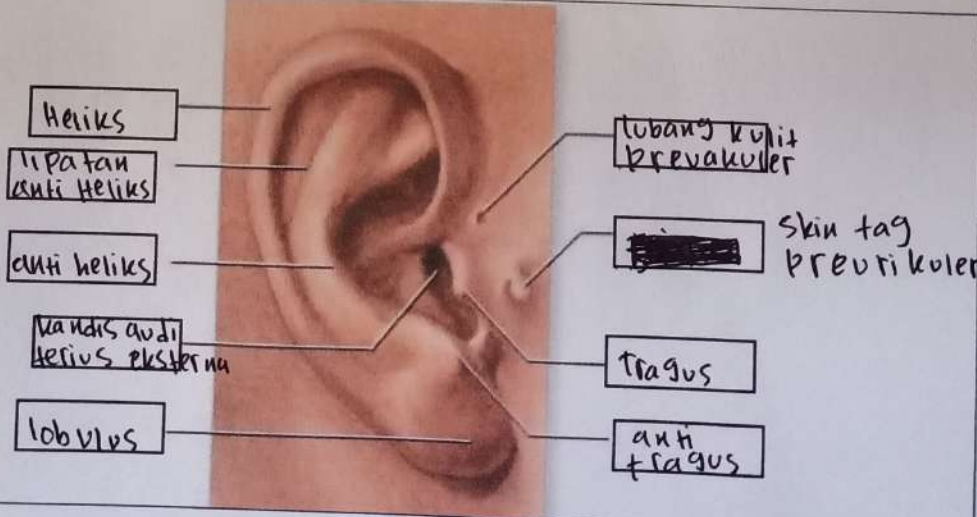


WORKSHEETS (LEMBAR KERJA)

Mata Kuliah	: Anatomi
Materi	: Anatomi Panca Indra
NIM>Nama Mahasiswa	: 2110101094 (ANNISA A KHAIRIYAH)

No	Keterangan	Pembahasan
1	Mata	 <p>Superior rectum</p> <p>Kornea</p> <p>Iris</p> <p>Pupil</p> <p>Lensa</p> <p>Retina</p> <p>Saraf optik</p>
	Telinga	 <p>Daun telinga</p> <p>Tulang telinga</p> <p>Rumah siput</p> <p>Saraf ke otak</p> <p>Gendang telinga</p> <p>Saluran eustachius</p> <p>Lubang telinga</p>
		 <p>Heliks</p> <p>Lipatan anti heliks</p> <p>Anti heliks</p> <p>Mandibula auris eksterna</p> <p>Lobulus</p> <p>Lubang kulit preaurikuler</p> <p>Skin tag preaurikuler</p> <p>Tragus</p> <p>Anti tragus</p>

No	Keterangan	Pembahasan
----	------------	------------




Diagram of the human ear with the following labels:

- Posterior semicircular canal
- Lateral semicircular canal
- Vestibuli
- Superior semicircular canal
- Nervus vestibularis
- Nervus cochlearis
- Cochea

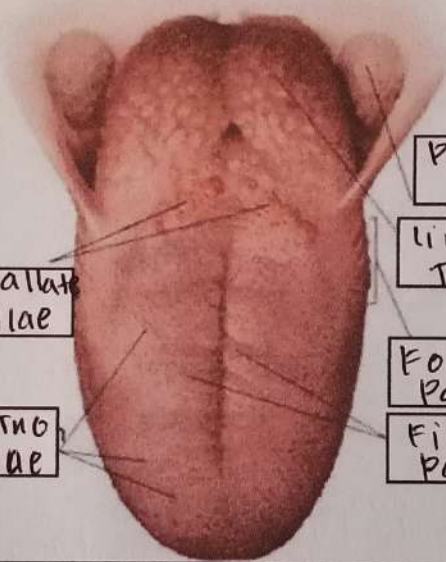


Diagram of the human tongue with the following labels:

- Circumvallata Papillae
- Fungiform Papillae
- Palatine tonsil
- Lingual Tonsil
- Foliate Papillae
- Filiform Papillae