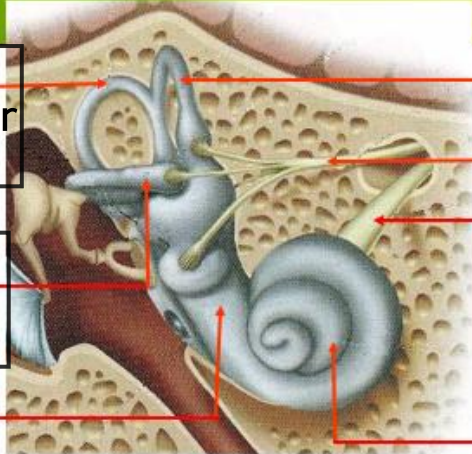
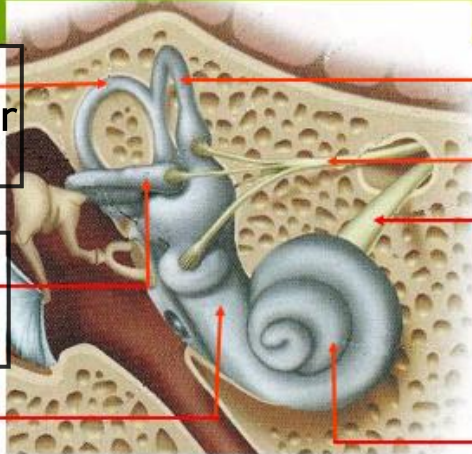
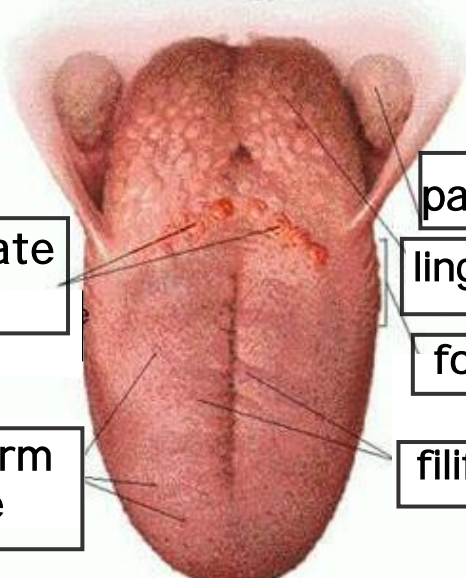
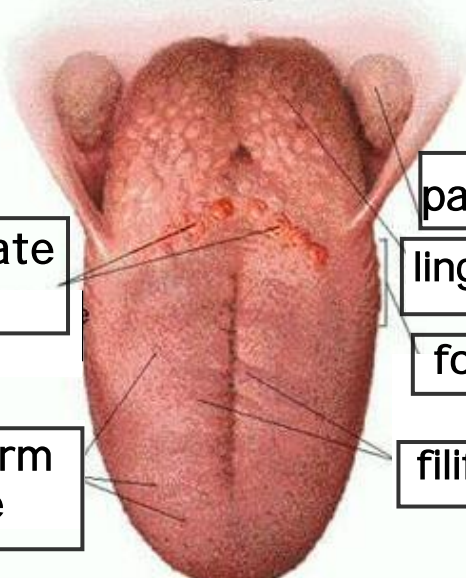


WORKSHEETS (LEMBAR KERJA)

Mata Kuliah	: Anatomi
Materi	: Anatomi Panca Indra
NIM>Nama Mahasiswa	: 2110101130 selina agustin siswandi

No	Keterangan	Pembahasan
1	Mata	<p>Diagram of the human eye showing internal structures. Labels include: otot mata (eye muscle), kornea (cornea), iris, pupil, lensa (lens), retina, and saraf (nerve).</p>
	Telinga	<p>Diagram of the middle ear showing the ossicles and other structures. Labels include: daun telinga (pinna), tulang telinga (ear bones), rumah siput (cochlea), saraf ke otak (nerve to brain), gendang telinga (eardrum), lubang telinga (ear canal), and saluran eustashius (Eustachian tube).</p>
		<p>Photograph of a human ear with external features labeled. Labels include: heliks (helix), lipatan antiheliks (antihelical fold), antiheliks (antihelix), analis auditorius eksterna (external auditory meatus), lobulus (lobule), lubang kulit preaurikuler (preauricular skin pit), skin tag preaurikuler (preauricular skin tag), tragus, and antitragus.</p>

No	Keterangan	Pembahasan
	 <p data-bbox="225 315 491 456">posterior semicircular canal</p> <p data-bbox="225 501 491 642">lateral semicircular canal</p> <p data-bbox="288 658 464 723">vestibuli</p>	 <p data-bbox="975 315 1353 412">superior semicircular canal</p> <p data-bbox="975 412 1353 463">nervus vestibularis</p> <p data-bbox="975 501 1219 629">nervus cochlearis</p> <p data-bbox="975 658 1187 723">cochlea</p>
	 <p data-bbox="352 949 660 1068">circumvallate papillae</p> <p data-bbox="405 1151 671 1279">fungiform papillae</p>	 <p data-bbox="995 882 1331 965">palatine tonsil</p> <p data-bbox="995 972 1331 1055">lingual tonsil</p> <p data-bbox="995 1061 1331 1144">foliate papillae</p> <p data-bbox="995 1173 1331 1256">filiform papillae</p>