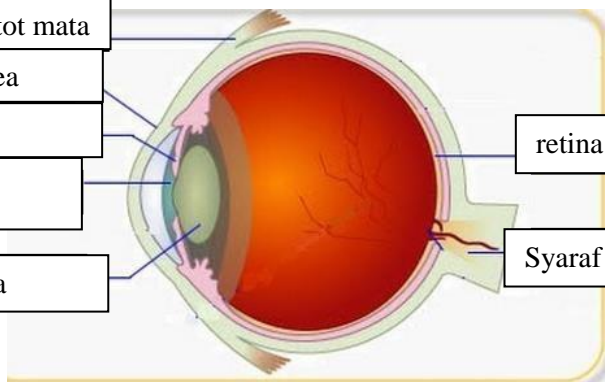
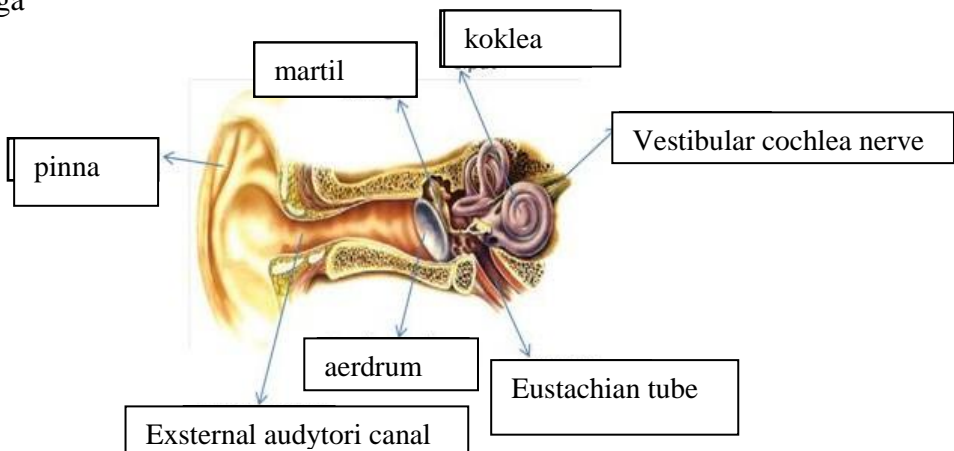



**WORKSHEETS (LEMBAR KERJA)**


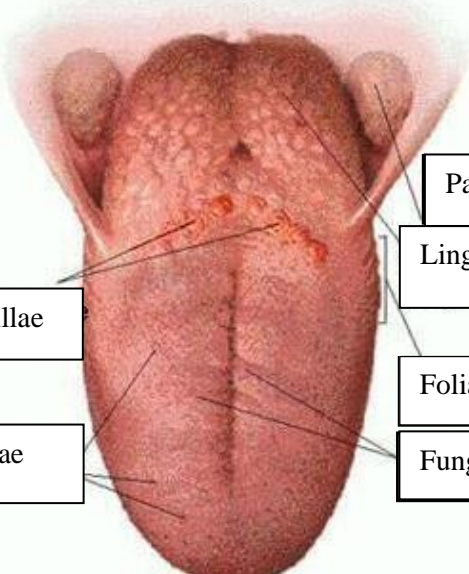
<b>Mata Kuliah</b>	: <b>Anatomi</b>
<b>Materi</b>	: <b>Anatomi Panca Indra</b>
<b>NIM&gt;Nama Mahasiswa</b>	: <b>MUSYAROFAH /2110101129</b>

No	Keterangan	Pembahasan
----	------------	------------

<p>Mata</p> <p>Otot mata</p> <p>kornea</p> <p>iris</p> <p>pupil</p> <p>lensa</p>		<p>retina</p> <p>Syaraf otak</p>
--	---	----------------------------------

<p>Telinga</p>		<p>koklea</p> <p>Vestibular cochlea nerve</p> <p>aerdrum</p> <p>Eustachian tube</p>
----------------	---	---

<p>helikes</p> <p>Lipatan antihelikes</p> <p>antihelikes</p> <p>Kanalis auditorius eksterna</p> <p>lobulus</p>		<p>preauikuler</p> <p>Skin tag preauikuler</p> <p>tragus</p> <p>antitragus</p>
--	---	--

No	Keterangan	Pembahasan
	<p data-bbox="225 327 456 405">Canalis semisirkularis</p> <p data-bbox="225 483 456 562">vestibulus</p> <p data-bbox="288 663 456 719">vestibule</p>	 <p data-bbox="991 327 1254 405">Semicircular canals</p> <p data-bbox="991 439 1254 506">Vestibular nerve</p> <p data-bbox="991 551 1158 629">saraf</p> <p data-bbox="991 663 1206 719">koklea</p>
	<p data-bbox="264 1032 671 1099">Circumvalate lingual papillae</p> <p data-bbox="304 1167 671 1234">Filiform lingual papillae</p>	 <p data-bbox="991 898 1254 965">Palatine tonsil</p> <p data-bbox="991 976 1238 1043">Lingual tonsil</p> <p data-bbox="991 1099 1238 1167">Foliate papilla</p> <p data-bbox="991 1178 1382 1245">Fungiform lingual papillae</p>