

WORKSHEETS (LEMBAR KERJA)

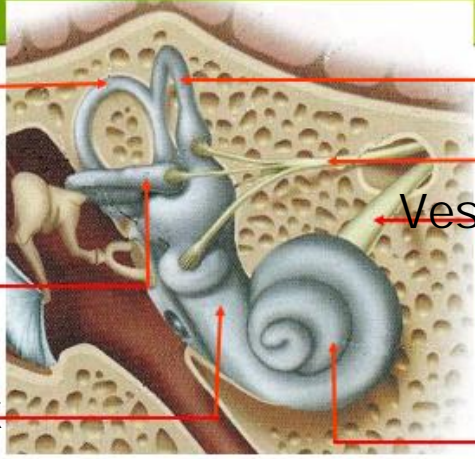
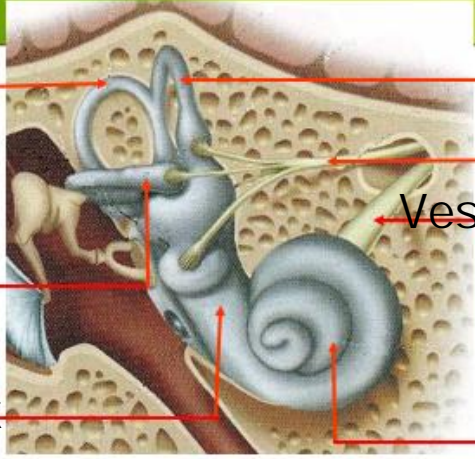
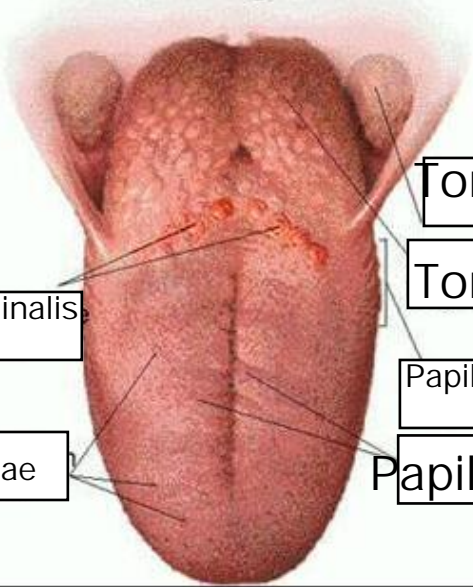
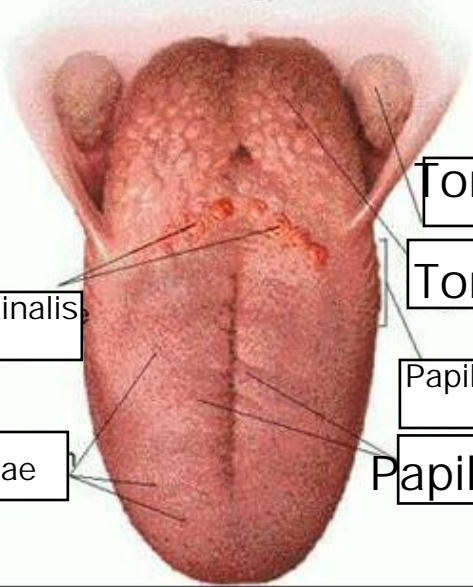
Mata Kuliah	: Anatomi
Materi	: Anatomi Panca Indra
NIM>Nama Mahasiswa	2110101124 Nurul sabillah

No	Keterangan	Pembahasan
----	------------	------------

1	Mata	<p>An anatomical diagram of the human eye in cross-section. Labels on the left side include: Otot mata (eye muscle), Cornea, Iris, Pupil, and Lens. Labels on the right side include: Retina and Central artery and vein of the retina.</p>
---	------	---

	Telinga	<p>An anatomical diagram of the human ear showing internal structures. Labels include: Auricle, Tympanic cavity, Cochlea, Cochlear branch of n viii, Tympanic Membrane, External acoustic meatus, and To nasopharynx.</p>
--	---------	---

		<p>A photograph of a human ear with anatomical labels. On the left: Helix, Scapha, Antihelix, Concha auriculaea, Lobulus auriculaea. On the right: Lubang kulit preaurikuler, Skin tag preaurikuler, Incisura anterior, Incisura Intertragica.</p>
--	--	--

No	Keterangan	Pembahasan
<p data-bbox="33 658 272 707">Vestibular complex</p>		 <p data-bbox="874 456 1474 506">Vestibular branch of n viii</p> <p data-bbox="951 562 1522 611">Cochlear branch of n viii</p> <p data-bbox="995 658 1177 707">Cochlea</p>
		 <p data-bbox="1007 898 1362 947">Tonsila palatina</p> <p data-bbox="1007 994 1362 1043">Tonsila lingualis</p> <p data-bbox="995 1090 1310 1140">Papila circum valate</p> <p data-bbox="963 1187 1378 1236">Papila fungiformis</p> <p data-bbox="405 1025 671 1075">Sulcus terminalis</p> <p data-bbox="389 1187 655 1236">Dorsum linguae</p>