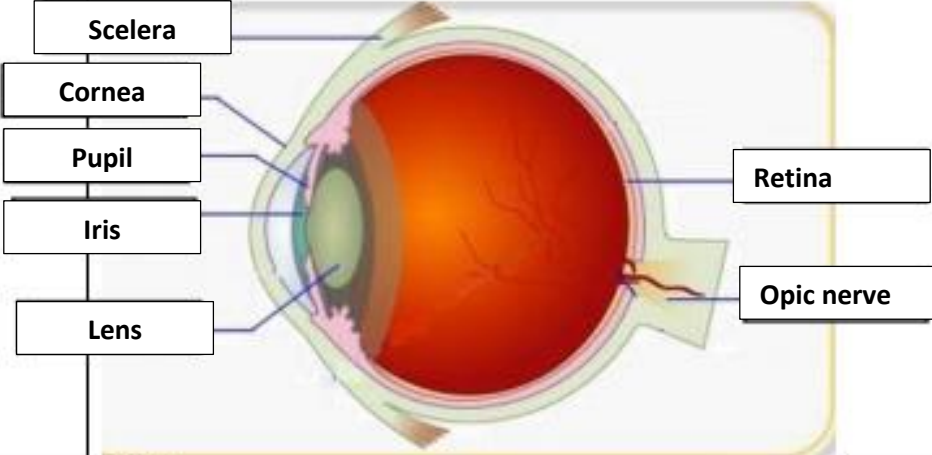
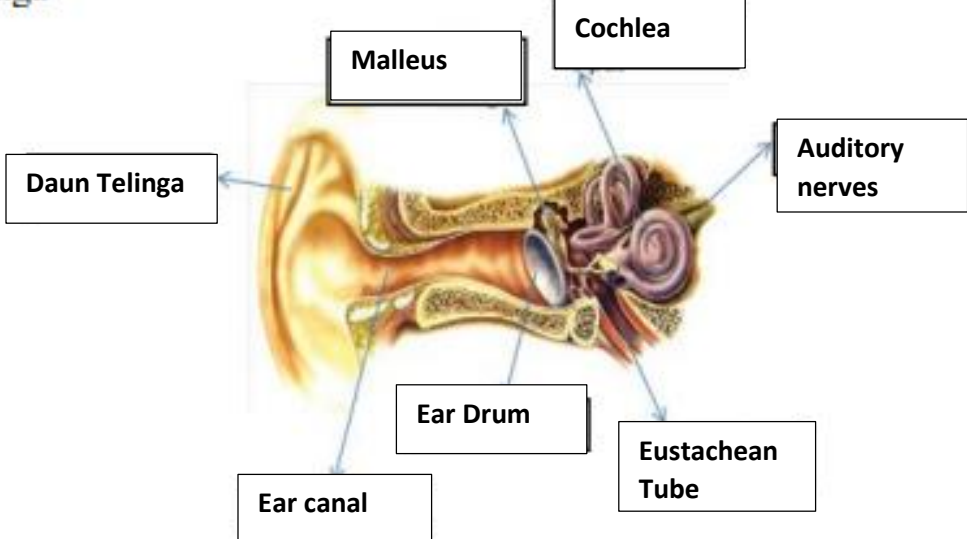
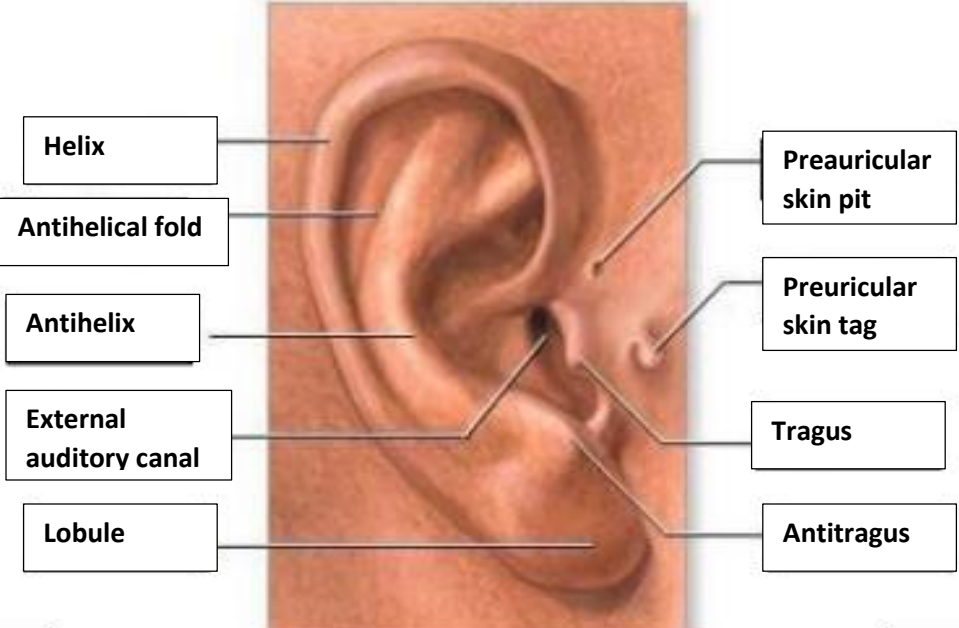


WORKSHEETS (LEMBAR KERJA)

Mata Kuliah : Anatomi

Materi : Anatomi Panca Indra

NIM>Nama Mahasiswa : Salsa Alima Azzahra / 2110101114

No	Keterangan	Pembahasan
1	<p>Mata</p>  <p>Scelera</p> <p>Cornea</p> <p>Pupil</p> <p>Iris</p> <p>Lens</p> <p>Retina</p> <p>Opic nerve</p>	
	<p>Telinga</p>  <p>Daun Telinga</p> <p>Malleus</p> <p>Cochlea</p> <p>Ear Drum</p> <p>Ear canal</p> <p>Eustachean Tube</p> <p>Auditory nerves</p>	 <p>Helix</p> <p>Antihelical fold</p> <p>Antihelix</p> <p>External auditory canal</p> <p>Lobule</p> <p>Preauricular skin pit</p> <p>Preuricular skin tag</p> <p>Tragus</p> <p>Antitragus</p>

No	Keterangan	Pembahasan
	