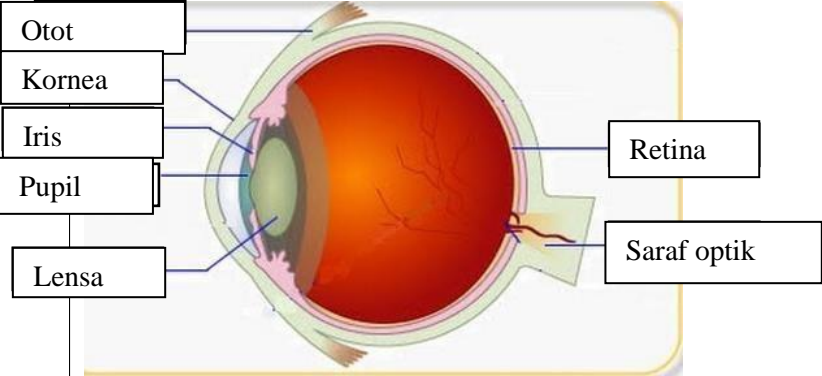
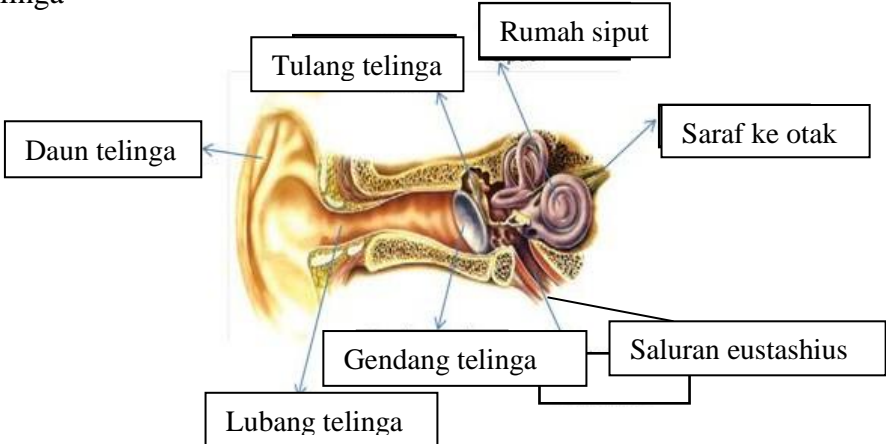
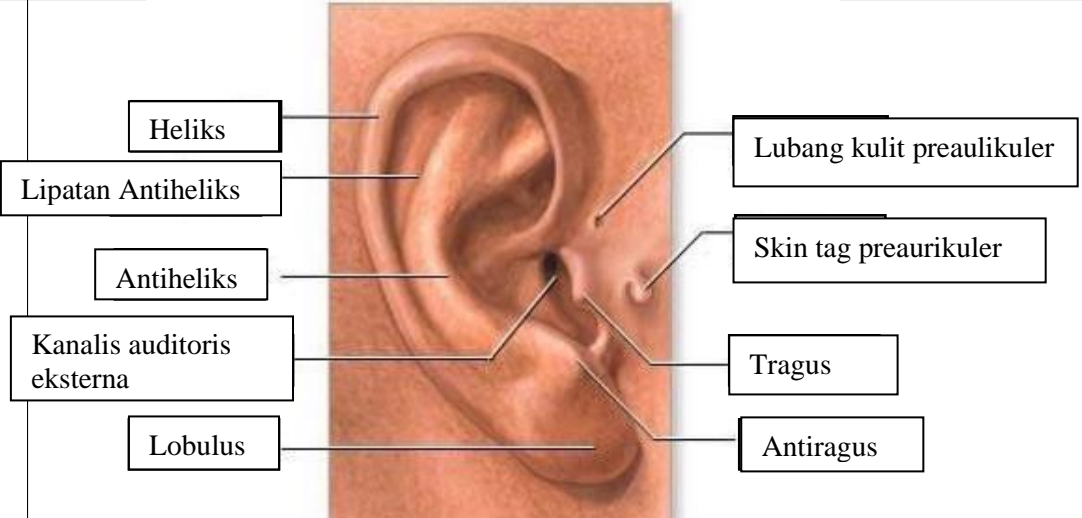
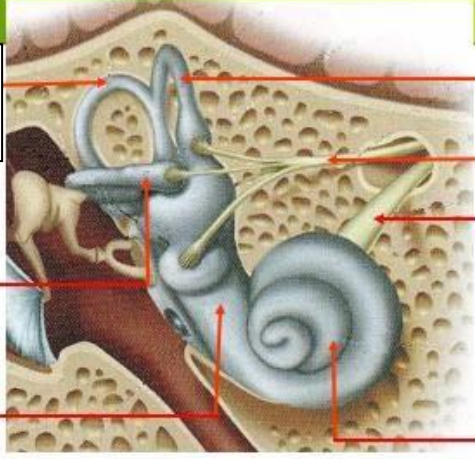
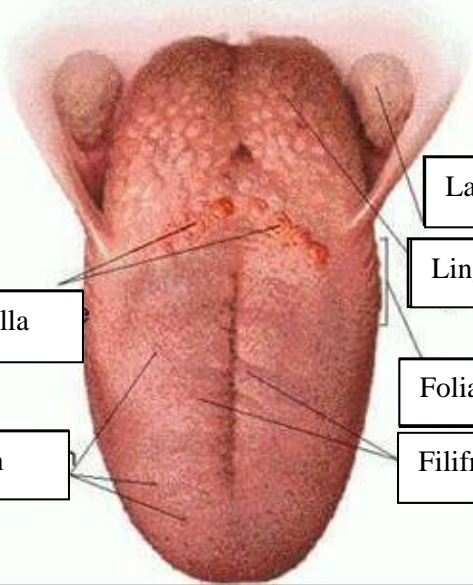


**WORKSHEETS (LEMBAR KERJA)**

<b>Mata Kuliah</b>	: Anatomi
<b>Materi</b>	: Anatomi Panca Indra
<b>NIM&gt;Nama Mahasiswa</b>	: 2110101112/ Mufidah

No	Keterangan	Pembahasan
1	<p>Mata</p> 	
	<p>Telinga</p> 	
		

No	Keterangan	Pembahasan
	 <p data-bbox="268 320 475 432">Semicircular Canals</p> <p data-bbox="248 488 456 577">Vestibular complex</p> <p data-bbox="225 656 456 723">Tingkap bundar</p>	 <p data-bbox="1002 331 1334 421">Semicircular duct within anterior semicircular</p> <p data-bbox="994 450 1297 573">1. Malleus 2. Incus 3. Stapes</p> <p data-bbox="1002 584 1214 640">Saraf kolesera</p> <p data-bbox="1002 663 1326 730">Konklev (rumah siput)</p> <p data-bbox="1018 909 1382 965">Langit-langit tenggorokan</p> <p data-bbox="1002 987 1241 1043">Lingual tonsil</p> <p data-bbox="344 1032 675 1099">Circumvallate papilla</p> <p data-bbox="384 1178 663 1234">Papil fungiform</p> <p data-bbox="994 1099 1254 1155">Foliate papillae</p> <p data-bbox="994 1178 1241 1234">Filiform papillae</p>