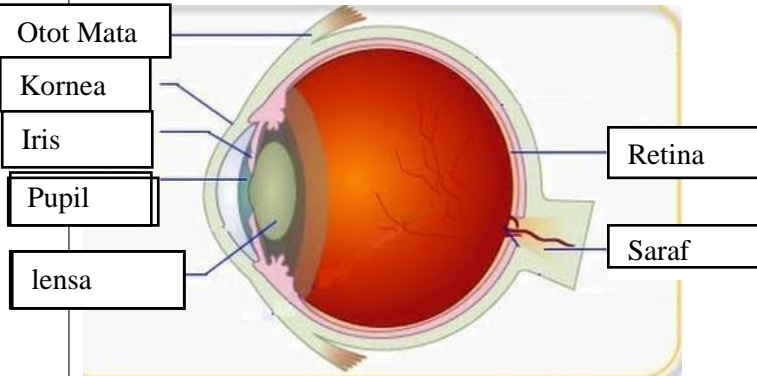
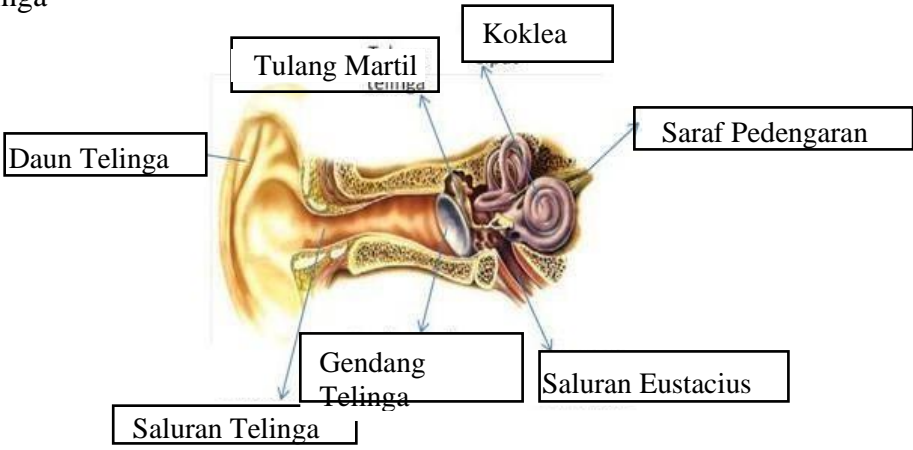
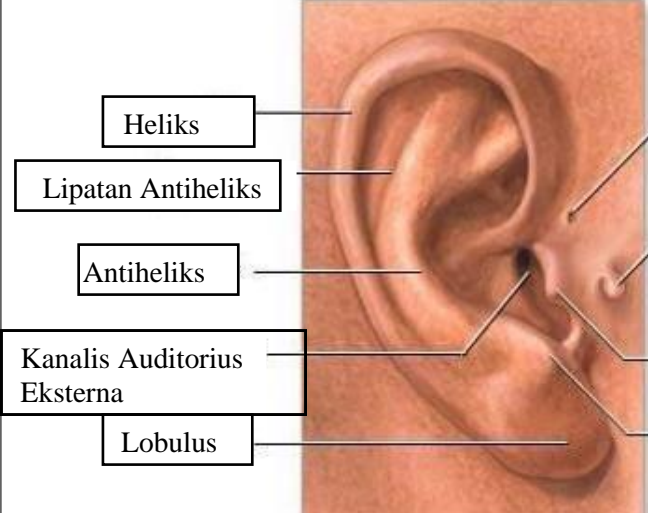
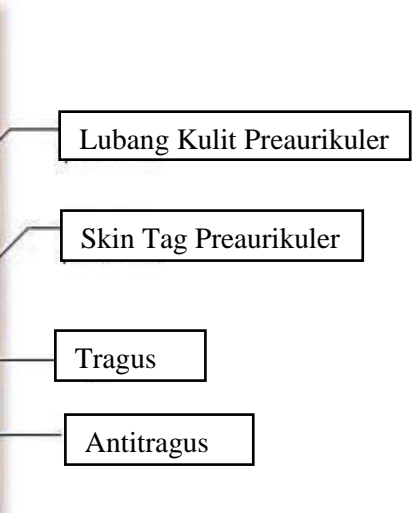
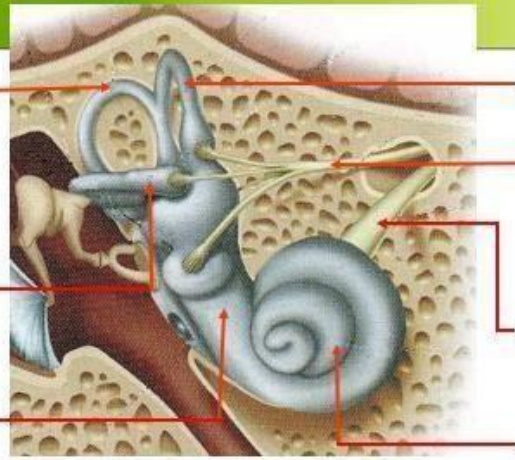
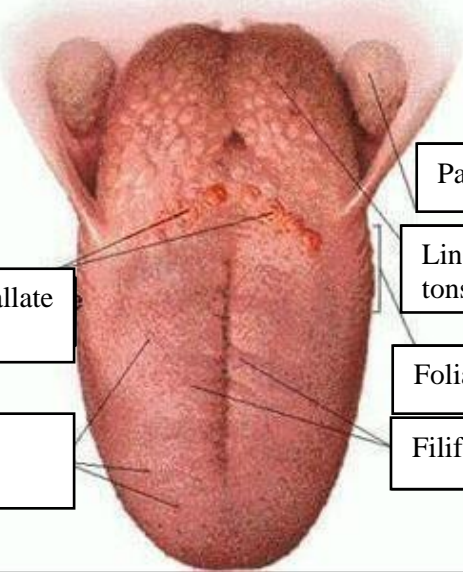


WORKSHEETS (LEMBAR KERJA)

Mata Kuliah	: Anatomi
Materi	: Anatomi Panca Indra
NIM>Nama Mahasiswa	: Rahmi Maisarah

No	Keterangan	Pembahasan
1	<p>Mata</p> 	
	<p>Telinga</p> 	
		

No	Keterangan	Pembahasan
	<div data-bbox="268 315 467 434" style="border: 1px solid black; padding: 2px;">Posterior Semicircular Canal</div> <div data-bbox="248 472 459 591" style="border: 1px solid black; padding: 2px;">Lateral Semicircular Canal</div> <div data-bbox="300 651 459 696" style="border: 1px solid black; padding: 2px;">Vestibuli</div>	 <div data-bbox="1002 315 1241 434" style="border: 1px solid black; padding: 2px;">Superior Semicircular Canal</div> <div data-bbox="1002 450 1273 510" style="border: 1px solid black; padding: 2px;">Nervus Vestibularis</div> <div data-bbox="1002 568 1278 629" style="border: 1px solid black; padding: 2px;">Nervus Cochlearis</div> <div data-bbox="1002 667 1161 728" style="border: 1px solid black; padding: 2px;">Cochlea</div>
	<div data-bbox="464 1025 676 1115" style="border: 1px solid black; padding: 2px;">Circumvallate papillae</div> <div data-bbox="451 1167 676 1256" style="border: 1px solid black; padding: 2px;">Fungiform papillae</div>	 <div data-bbox="991 898 1241 965" style="border: 1px solid black; padding: 2px;">Palatine tonsil</div> <div data-bbox="991 981 1198 1070" style="border: 1px solid black; padding: 2px;">Lingual tonsil</div> <div data-bbox="991 1099 1241 1167" style="border: 1px solid black; padding: 2px;">Foliate papillae</div> <div data-bbox="991 1182 1241 1249" style="border: 1px solid black; padding: 2px;">Filiform papillae</div>