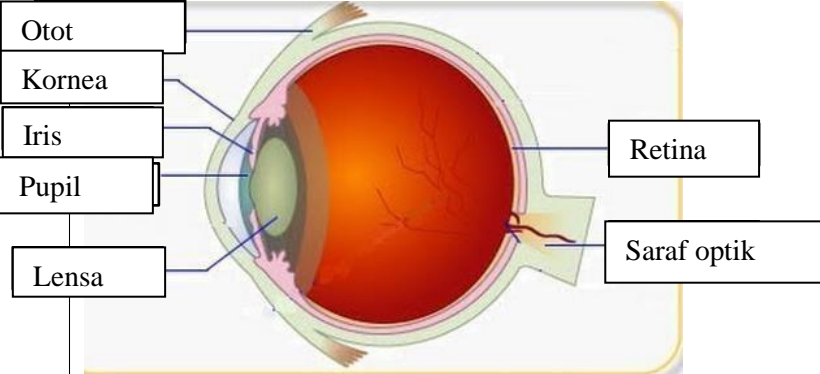

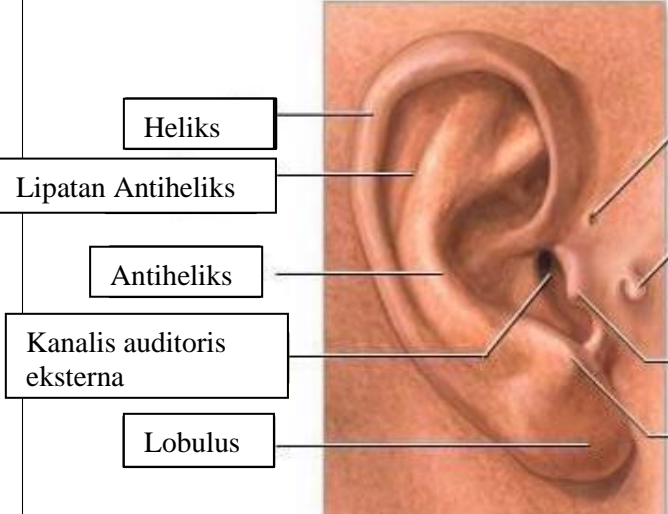
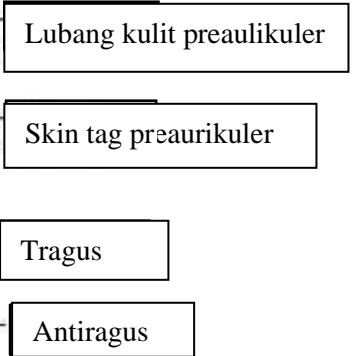
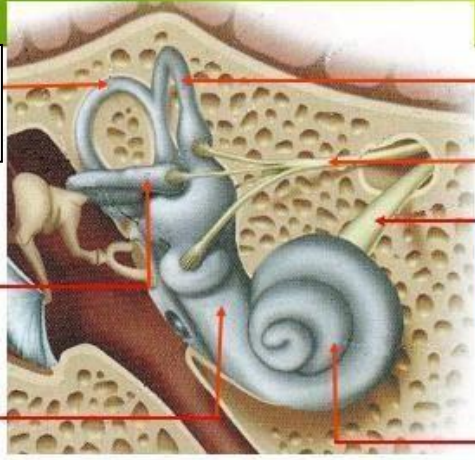
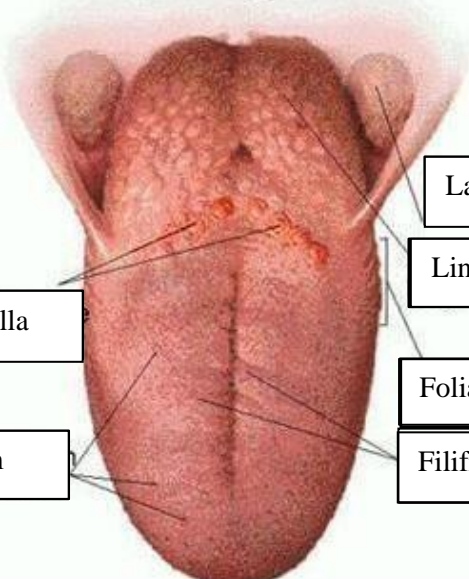


**WORKSHEETS (LEMBAR KERJA)**

<b>Mata Kuliah</b>	: Anatomi
<b>Materi</b>	: Anatomi Panca Indra
<b>NIM&gt;Nama Mahasiswa</b>	: 2110101077/ PUTRI ANGGRAINI

No	Keterangan	Pembahasan
1	<p>Mata</p> 	
	<p>Telinga</p> 	
		

No	Keterangan	Pembahasan
	 <p data-bbox="268 315 475 432">Semicircular Canals</p> <p data-bbox="245 488 456 582">Vestibular complex</p> <p data-bbox="225 651 456 723">Tingkap bundar</p>	<p data-bbox="1002 331 1329 416">Semicircular duct within anterior semicircular</p> <p data-bbox="1002 443 1294 573">1. Malleus 2. Incus 3. Stapes</p> <p data-bbox="1002 584 1209 645">Saraf kolesera</p> <p data-bbox="1002 663 1321 723">Konklev (rumah siput)</p>
	 <p data-bbox="341 1032 671 1104">Circumvallate papilla</p> <p data-bbox="384 1171 660 1243">Papil fungiform</p>	<p data-bbox="1018 902 1377 963">Langit-langit tenggorokan</p> <p data-bbox="1018 981 1241 1041">Lingual tonsil</p> <p data-bbox="1002 1099 1249 1160">Foliate papillae</p> <p data-bbox="1002 1171 1241 1243">Filiform papillae</p>