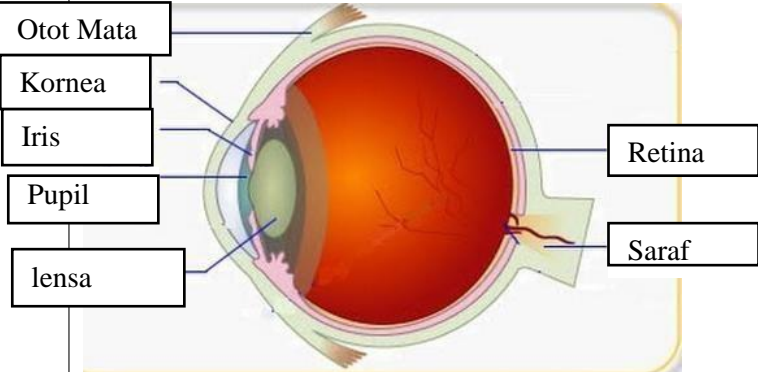
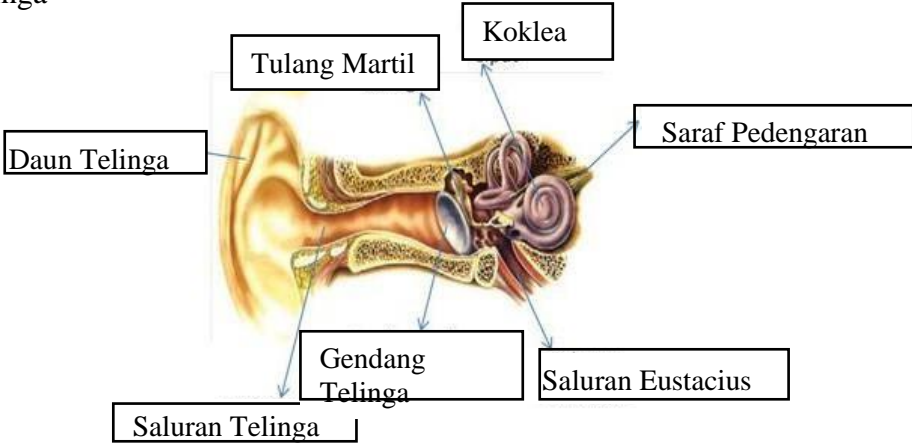
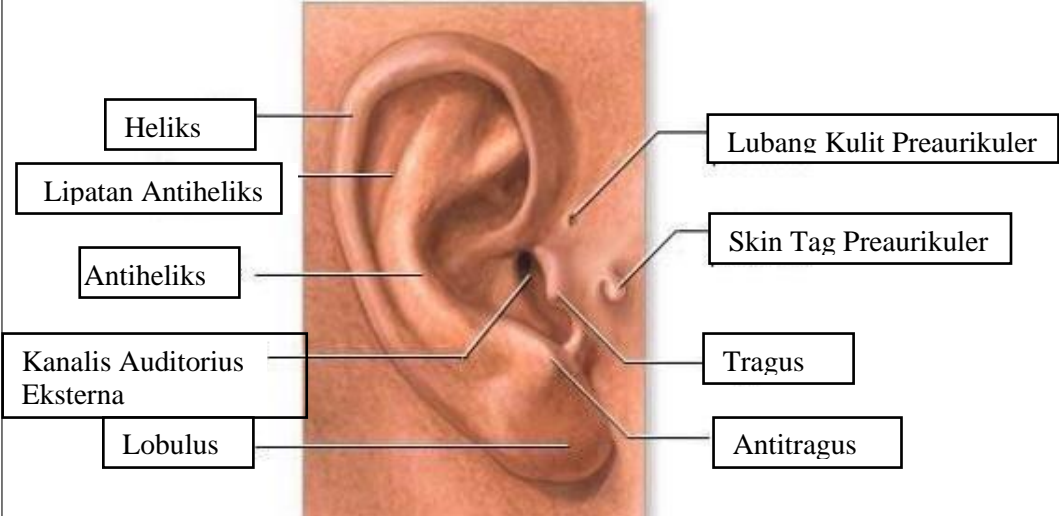
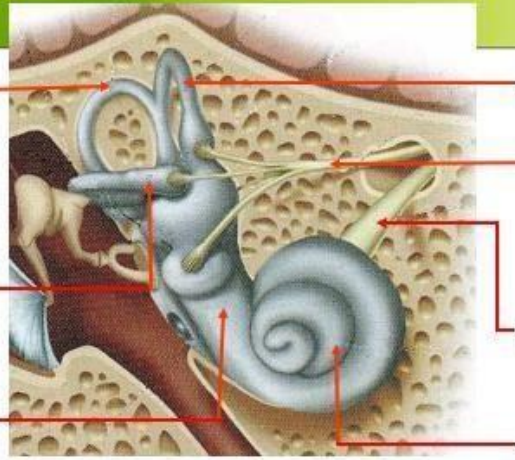
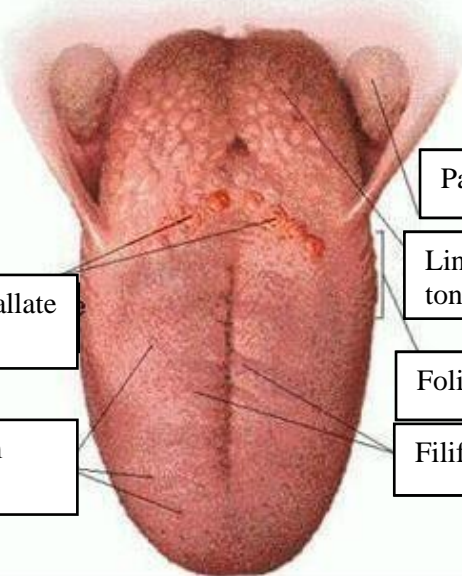


WORKSHEETS (LEMBAR KERJA)

Mata Kuliah	: Anatomi
Materi	: Anatomi Panca Indra
NIM>Nama Mahasiswa	: FATIMAH AZZAHRA/ 2110101106

No	Keterangan	Pembahasan
1	<p>Mata</p> 	
	<p>Telinga</p> 	
		

No	Keterangan	Pembahasan
	<div data-bbox="268 320 466 434" style="border: 1px solid black; padding: 2px;">Posterior Semicircular Canal</div> <div data-bbox="247 472 458 593" style="border: 1px solid black; padding: 2px;">Lateral Semicircular Canal</div> <div data-bbox="290 651 458 696" style="border: 1px solid black; padding: 2px;">Vestibuli</div>	 <div data-bbox="1002 320 1238 434" style="border: 1px solid black; padding: 2px;">Superior Semicircular Canal</div> <div data-bbox="1002 450 1273 510" style="border: 1px solid black; padding: 2px;">Nervus Vestibularis</div> <div data-bbox="1002 568 1273 629" style="border: 1px solid black; padding: 2px;">Nervus Cochlearis</div> <div data-bbox="1002 667 1161 728" style="border: 1px solid black; padding: 2px;">Cochlea</div>
	<div data-bbox="461 1025 673 1111" style="border: 1px solid black; padding: 2px;">Circumvallate papillae</div> <div data-bbox="450 1171 673 1256" style="border: 1px solid black; padding: 2px;">Fungiform papillae</div>	 <div data-bbox="991 898 1238 965" style="border: 1px solid black; padding: 2px;">Palatine tonsil</div> <div data-bbox="991 981 1198 1066" style="border: 1px solid black; padding: 2px;">Lingual tonsil</div> <div data-bbox="991 1099 1238 1167" style="border: 1px solid black; padding: 2px;">Foliate papillae</div> <div data-bbox="991 1182 1238 1249" style="border: 1px solid black; padding: 2px;">Filiform papillae</div>