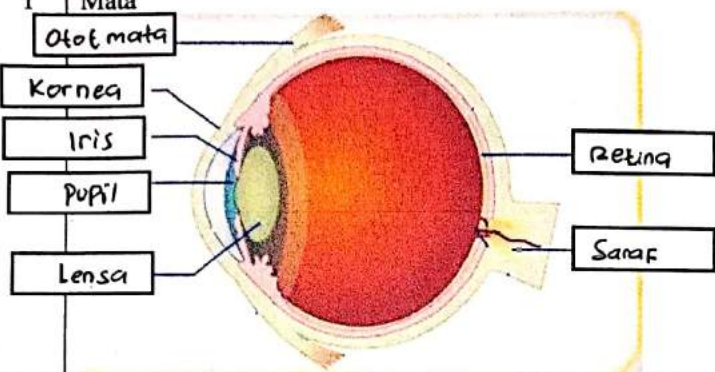
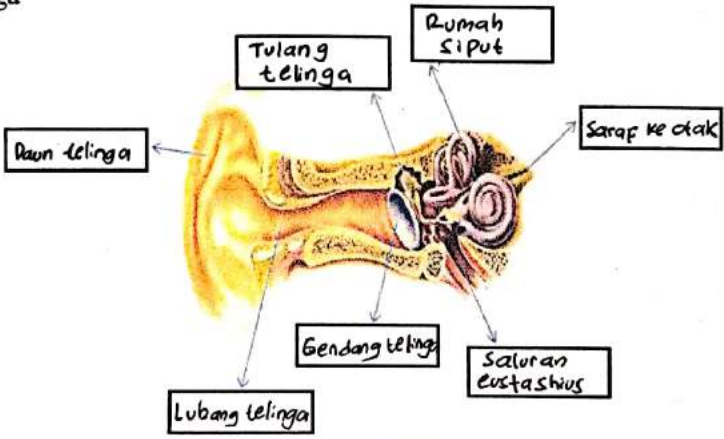
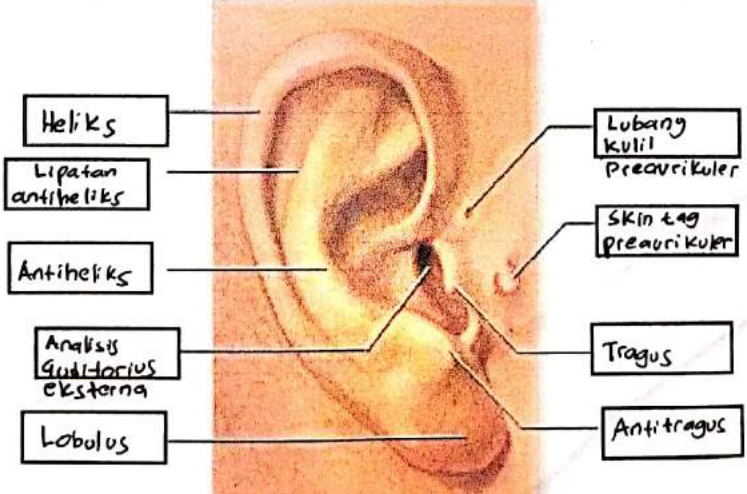

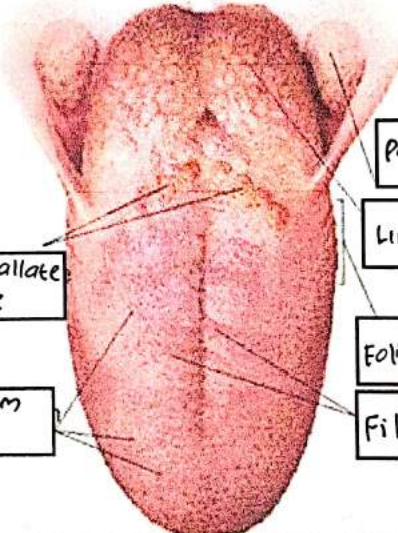


WORKSHEETS (LEMBAR KERJA)

Mata Kuliah	: Anatomi
Materi	: Anatomi Panca Indra
NIM>Nama Mahasiswa	: 2110101101/Shinta Elmanora

No	Keterangan	Pembahasan
1	Mata	 <p>Diagram of the human eye showing internal structures. Labels include: Otot mata (eye muscle), Kornea (cornea), Iris, Pupil, Lensa (lens), Retina, and Saraf (nerve).</p>
	Telinga	 <p>Diagram of the middle ear showing the ossicles and other structures. Labels include: Daun telinga (pinna), Tulang telinga (ear bones), Rumah siput (snail house), Saraf ke otak (nerve to brain), Gendang telinga (eardrum), Saluran Eustachius (Eustachian tube), and Lubang telinga (ear canal).</p>
		 <p>Diagram of the external ear showing its various parts. Labels include: Heliks (helix), Lipatan antiheliks (antihelix fold), Antiheliks (antihelix), Analis Guditarius eksterna (external auditory meatus), Lobulus (lobule), Lubang kulit preaurikuler (preauricular skin pit), Skin tag preaurikuler (preauricular skin tag), Tragus, and Antitragus.</p>

No	Keterangan	Pembahasan
	<p>Posterior semicircular canal</p> <p>Lateral semicircular canal</p> <p>Vestibuli</p>	 <p>Superior semicircular canal</p> <p>Nervus Vestibularis</p> <p>Nervus Cochlearis</p> <p>Cochlea</p>
	<p>Circumvallate papillae</p> <p>Fungiform papillae</p>	 <p>Palatine Tonsil</p> <p>Lingual Tonsil</p> <p>Foliate Papillae</p> <p>Filiform papillae</p>