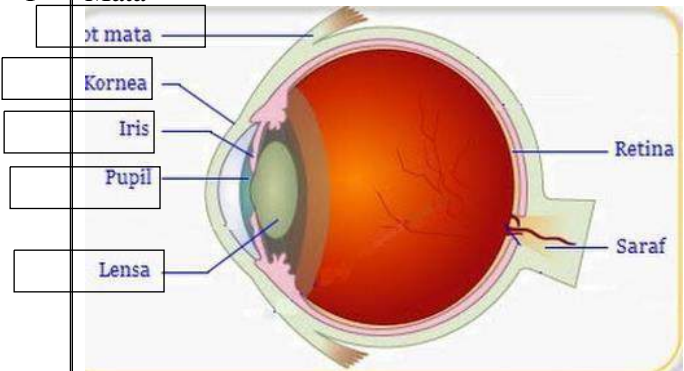

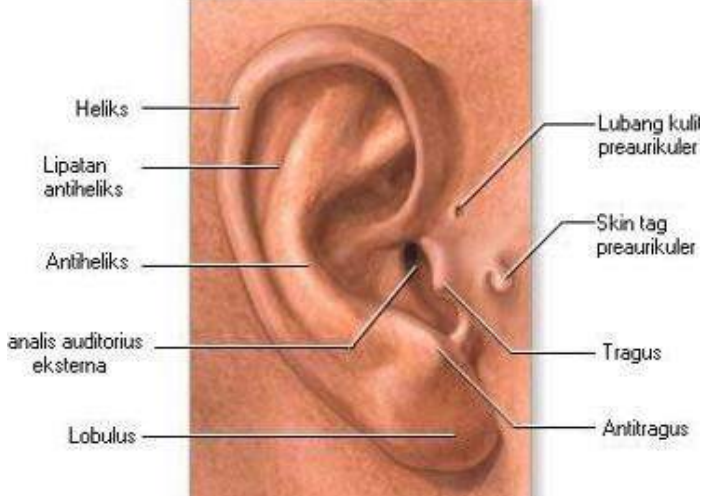
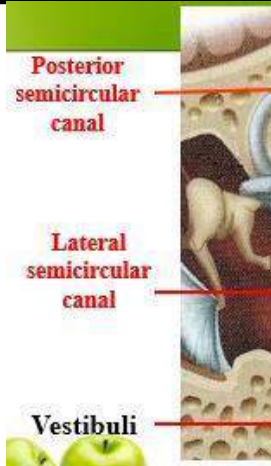
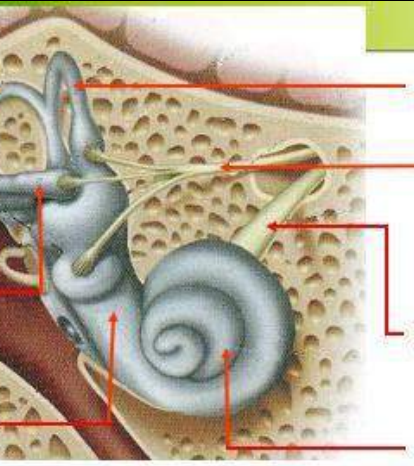
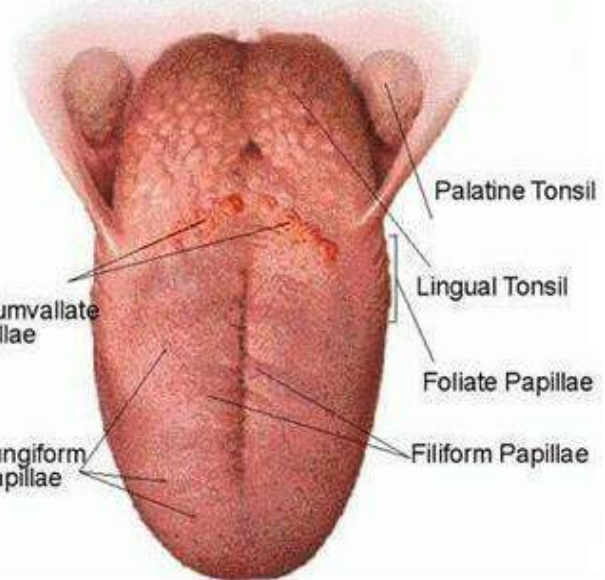


WORKSHEETS (LEMBAR KERJA)

Mata Kuliah	: Anatomi
Materi	: Anatomi Panca Indra
NIM>Nama Mahasiswa	: 2110101105/Shivani Nurrahmah Purnady

No	Keterangan	Pembahasan
1	<p>Mata</p>  <p>Diagram of the human eye showing internal structures. Labels on the left: Kornea, Iris, Pupil, Lensa. Labels on the right: Retina, Saraf.</p>	
	<p>Telinga</p>  <p>Diagram of the human ear showing internal structures. Labels: Daun telinga, Lubang telinga, Tulang telinga, Rumah siput, Gendang telinga, Saluran eustachius, Saraf ke otak.</p>	
		 <p>Diagram of the external ear showing various parts. Labels: Heliks, Lipatan antiheliks, Antiheliks, analis auditorius eksterna, Lobulus, Lubang kulit preaurikuler, Skin tag preaurikuler, Tragus, Antitragus.</p>

No	Keterangan	Pembahasan
	 <p>Posterior semicircular canal</p> <p>Lateral semicircular canal</p> <p>Vestibuli</p>	 <p>Superior semicircular canal</p> <p>Nervus Vestibularis</p> <p>Nervus Cochlearis</p> <p>Cochlea</p>
		 <p>Palatine Tonsil</p> <p>Lingual Tonsil</p> <p>Foliate Papillae</p> <p>Filiform Papillae</p> <p>Fungiform Papillae</p> <p>Circumvallate Papillae</p>