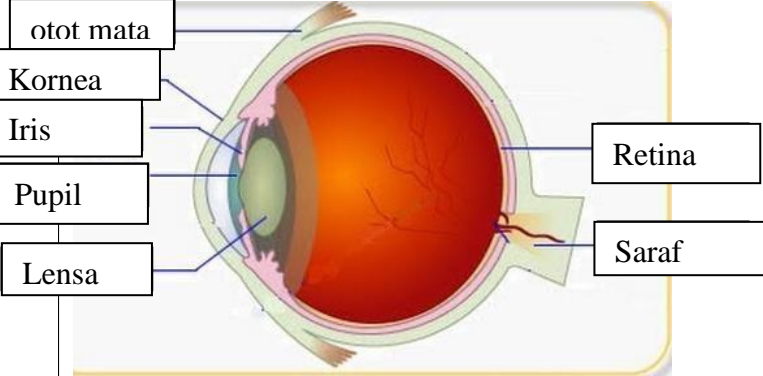
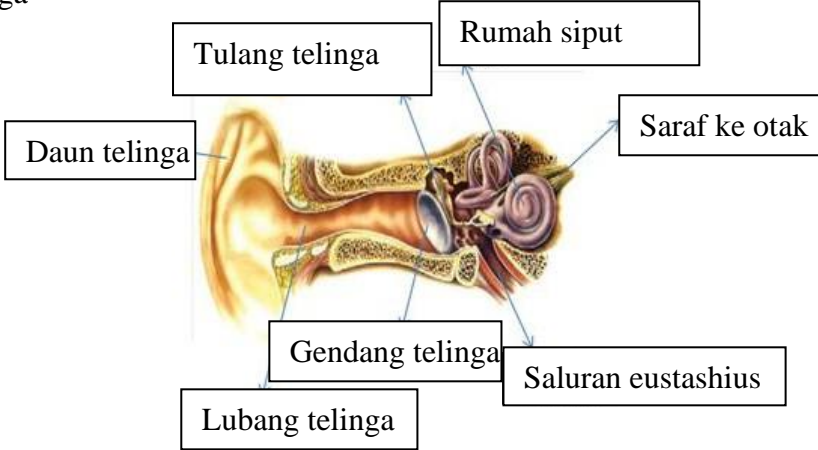
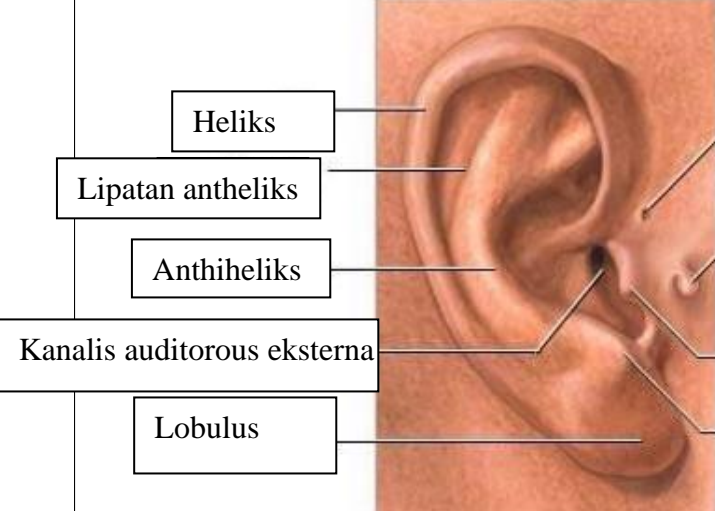
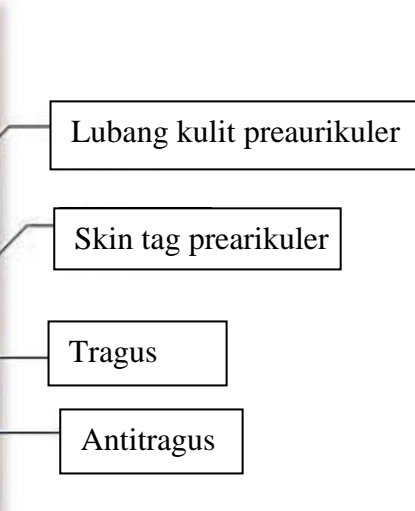
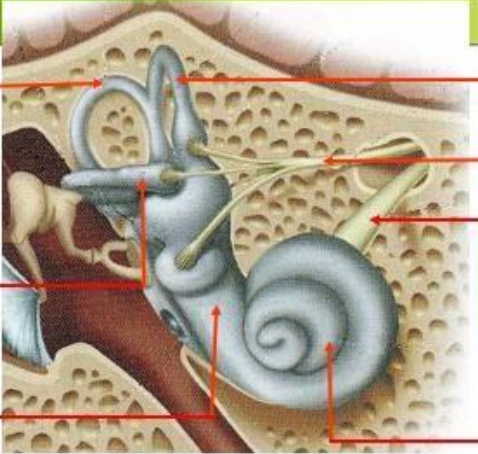
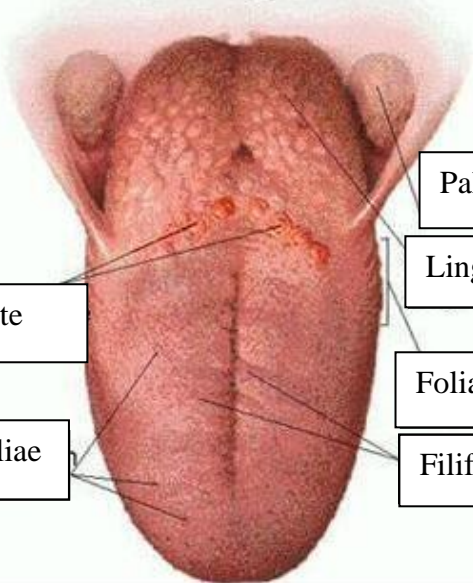


WORKSHEETS (LEMBAR KERJA)

Mata Kuliah	: Anatomi
Materi	: Anatomi Panca Indra
NIM>Nama Mahasiswa	: 2110101107/Fitriana Ardiansah

No	Keterangan	Pembahasan
1	<p>Mata</p> 	
	<p>Telinga</p> 	
		

No	Keterangan	Pembahasan
	<div data-bbox="293 315 459 472">Posterior Semi circular Canal</div> <div data-bbox="293 483 459 640">Lateral Semicircular canal</div> <div data-bbox="293 651 459 723">vestibuli</div>	 <div data-bbox="995 315 1230 416">Superior semi circular canal</div> <div data-bbox="995 439 1230 539">Nervus vestibularis</div> <div data-bbox="995 562 1257 640">Nervus cochlearis</div> <div data-bbox="995 651 1169 723">Cochea</div>
	<div data-bbox="408 1021 676 1099">Circumvaliate</div> <div data-bbox="363 1155 660 1234">Fungiform papiliae</div>	 <div data-bbox="1007 887 1273 965">Palatine tonsil</div> <div data-bbox="1007 987 1257 1043">Lingual tonsil</div> <div data-bbox="995 1099 1225 1155">Foliate papilae</div> <div data-bbox="995 1178 1230 1234">Filiform papiliae</div>